

# Elsberg syndrome

## A rarely recognized cause of cauda equina syndrome and lower thoracic myelitis

OPEN

Filippo Savoldi, MD  
Timothy J. Kaufmann,  
MD  
Eoin P. Flanagan,  
MBBCh  
Michel Toledano, MD  
Brian G. Weinschenker,  
MD

Correspondence to  
Dr. Weinschenker:  
weinb@mayo.edu

### ABSTRACT

**Objective:** Elsberg syndrome (ES) is an established but often unrecognized cause of acute lumbosacral radiculitis with myelitis related to recent herpes virus infection. We defined ES, determined its frequency in patients with cauda equina syndrome (CES) with myelitis, and evaluated its clinical, radiologic, and microbiologic features and outcomes.

**Methods:** We searched the Mayo Clinic medical records for ES and subsequently for combinations of index terms to identify patients with suspected CES and myelitis.

**Results:** Our search yielded 30 patients, 2 diagnosed with ES and an additional 28 with clinical or radiologic evidence of CES retrospectively suspected of having ES. We classified patients in 5 groups according to diagnostic certainty. MRI and EMG confirmed that 2 had only myelitis, 5 only radiculitis, and 16 both. Two had preceding sacral herpes infection and 1 oral herpes simplex. Spinal cord lesions were commonly multiple, discontinuous, not expansile, and centrally or ventrally positioned. Lesions generally spared the distal conus. Nerve root enhancement was occasionally prominent and was smooth rather than nodular. Lymphocytic CSF pleocytosis was common. Thirteen patients (43%) had viral isolation studies, which were commonly delayed; the delay may have accounted for the low rate of viral detection. Acyclovir was administered to 6 patients. Most patients recovered with sequelae; 1 patient experienced encephalomyelitis and died.

**Conclusion:** ES is a definable condition likely responsible for 10% of patients with combined CES and myelitis. Radiologic findings are not entirely specific but may help in differentiating ES from some competing diagnostic considerations. We propose criteria to facilitate diagnosis. *Neurol Neuroimmunol Neuroinflamm* 2017;4:e355; doi: 10.1212/NXI.0000000000000355

### GLOSSARY

**CES** = cauda equina syndrome; **ES** = Elsberg syndrome; **HSV2** = herpes simplex virus 2; **ICD** = *International Classification of Disease*; **NMO** = neuromyelitis optica; **VZV** = varicella zoster virus.

Elsberg syndrome (ES) is a presumed infectious syndrome consisting of acute or subacute bilateral lumbosacral radiculitis, often accompanied by myelitis confined to the lower spinal cord, and is frequently a manifestation of reactivation, or occasionally, primary herpes simplex virus 2 (HSV2) infection.<sup>1</sup> Clinicians often do not consider ES in the differential diagnosis of acute cauda equina syndrome (CES) and do not perform appropriate testing for HSV infection in a timely way to facilitate definitive diagnosis. However, especially when accompanied by clinical or radiologic findings of myelitis, ES is not a rare cause of CES. ES has been the subject of case reports and small series,<sup>2–7</sup> the largest of which included 17 patients.<sup>8</sup> A formal case definition that defines the minimum criteria to diagnose this syndrome and identifies exclusionary findings that suggest alternative diagnoses does not exist. Sarcoidosis, lymphoma, other neoplasms, and vascular disorders (dural arteriovenous fistula) may mimic ES and are in the differential diagnosis.

From the Departments of Neurology (F.S., E.P.F., M.T., B.G.W.), and Neuroradiology (T.J.K.), Mayo Clinic, Rochester, MN; and Neuroimaging Research Unit (F.S.), Department of Neurology, San Raffaele Scientific Institute and University, Milan, Italy.

Funding information and disclosures are provided at the end of the article. Go to [Neurology.org/nn](http://Neurology.org/nn) for full disclosure forms. The Article Processing Charge was funded by the authors.

This is an open access article distributed under the terms of the Creative Commons Attribution-NonCommercial-NoDerivatives License 4.0 (CC BY-NC-ND), which permits downloading and sharing the work provided it is properly cited. The work cannot be changed in any way or used commercially without permission from the journal.

We conducted a retrospective review of lumbosacral myeloradiculitis evaluated at the Mayo Clinic to assess the frequency of ES, determined retrospectively as well as prospectively. Among cases who did not have other established diagnoses and who met certain minimum criteria, we reviewed Mayo clinical records to classify the level of diagnostic certainty using a scheme we derived based on a review of the medical literature (table 1). We identified clinical, demographic, and radiologic findings of ES, concentrating on distinction from other causes of lower thoracic/conus myelitis.

**METHODS** We performed a retrospective review of Mayo electronic medical records from 2000 to March 2016 interrogating for the term “Elsberg” in the history, examination, review of systems, impression, and final diagnosis and thereby identified

only 4 patients. To find unrecognized cases, we searched again for a combination of key terms common to those of the 4 ES cases in patients evaluated in the neurology, urology, gynecology, or infectious disease departments who had both myelitis and radiculitis (figure 1). After testing several possible combinations of terms, we selected patients identified by at least 1 of 4 searches of the medical records, components of which are highlighted in flow chart in figure 1, and thereby identified 1,035 patients. We excluded patients with an *International Classification of Disease (ICD)* diagnosis of MS or neuromyelitis optica (NMO), reducing the cohort to 837 subjects. Exclusion of cases without terms referring to urinary retention or sacral sensory symptoms further reduced the cohort to 337 subjects. A review of individual clinical records identified 213 patients with other definitive alternative diagnoses (table 2). Subsequently, we conducted a detailed review of clinical records to confirm the presence of urinary retention or other sacral symptoms (saddle anesthesia, paresthesias, neuralgic pain, constipation, impotence, urinary incontinence, and fecal incontinence) yielding 49 patients who were strongly suspected to have ES (figure 1). We abstracted their demographic characteristics, neurologic examination findings, CSF, viral, EMG, and MRI results from clinical records. The Mayo Clinic Institutional Review Board granted approval to review retrospectively obtained patient clinical information.

We defined diagnostic criteria for ES with 5 levels of diagnostic certainty based on the review of the medical literature: laboratory-supported definite, clinically definite, clinically probable, clinically possible, and excluded (table 1). Radiculitis, defined either clinically (table 1, A1) or by MRI and/or electrophysiologic evidence (table 1, A2), was required to establish a diagnosis of ES. A neurologist (B.G.W.) categorized each case according to these criteria and with special attention to potential alternative diagnoses. A neuroradiologist (T.K.) reviewed abnormal radiology to confirm and further characterize the abnormalities in each case and to consider whether there were unique or characteristic radiologic features of ES after the review of the entire cohort.

We report the frequencies of key clinical and radiologic features and summarize distinctive radiologic features.

**RESULTS** Forty-nine patients satisfied the inclusion and exclusion criteria. Clinical and MRI findings are summarized in table 3 and the clinical course in table 4. Three patients met criteria for laboratory-supported definite, 9 for clinically definite, 10 for clinically probable, and 8 for clinically possible ES. Nineteen patients were excluded, 16 (84%) because of exclusionary criteria (table 1) and 3 (16%) because they failed to satisfy any of the established levels of diagnostic certainty (table 1), including 2 of the 4 diagnosed with ES at the time of their clinical evaluation but with insufficient information to confirm the diagnosis. Based on MRI and EMG, available in 29 and 21 cases respectively, 2 patients had only myelitis, 5 only radiculitis, and 16 both. Only 2 included patients had been diagnosed with ES at the time of their clinical evaluation.

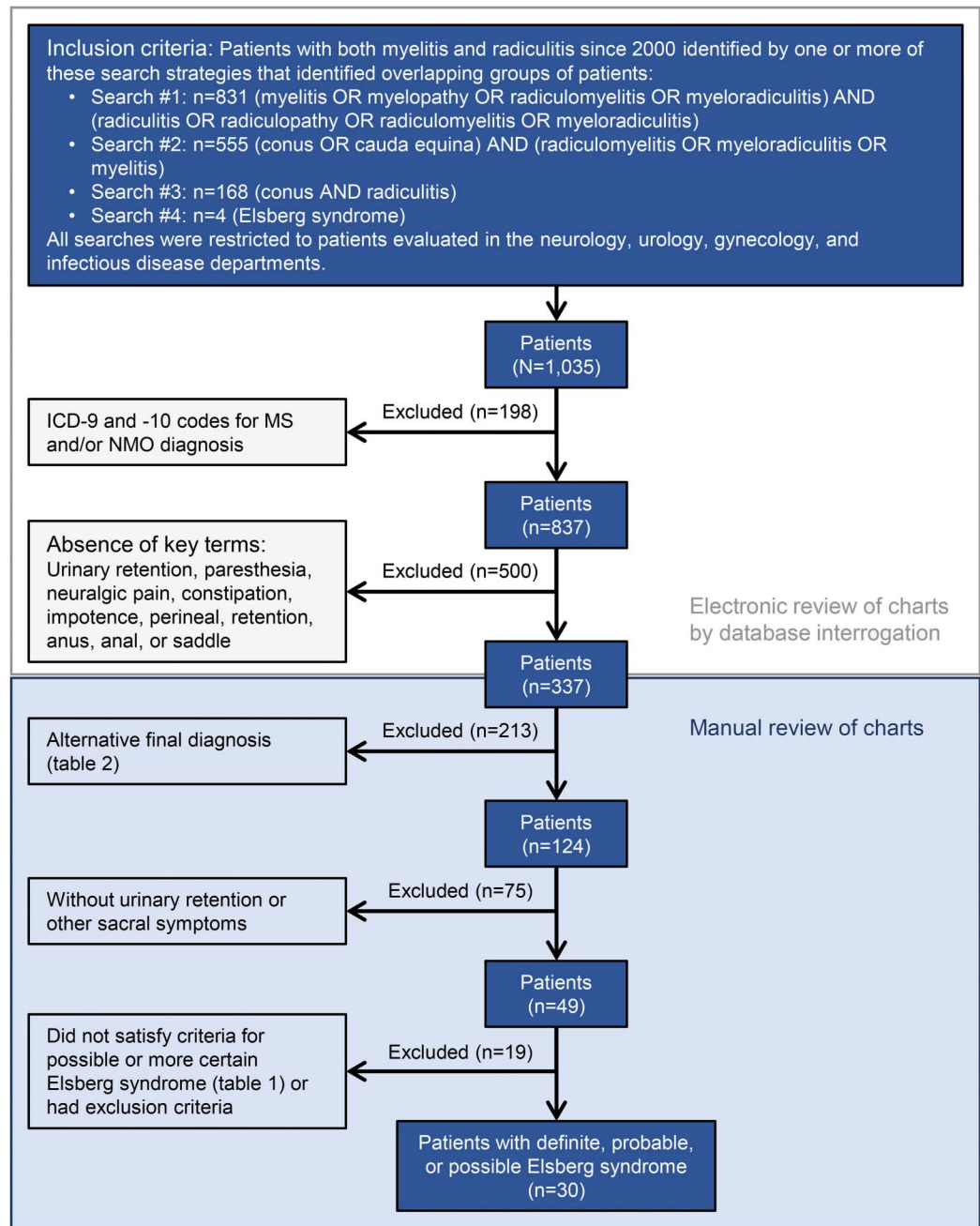
Of the 30 patients with a diagnosis of lab-supported, definite, probable, or possible ES, 24 (80%) were men and 6 women (20%) and their median age was 53 years. Five patients (17%) experienced prodromal symptoms, including fever, headache,

**Table 1** Elsberg syndrome according to diagnostic certainty

Categories	Criteria	No. of patients
1. Laboratory-supported definite	(A1 OR A2) AND B5	3
2. Clinically definite	A1 OR A2; B1 AND two of B2-B4; B1 and B2 (if concomitant)	9
3. Clinically probable	A1 OR A2; B1 AND one of B2-B4	10
4. Clinically possible	A1 OR A2; one of B1-B4	8
5. Excluded	Neither of A1 nor of A2; any of D1-D3	19
A. Required		
A1. Clinical symptoms and signs of cauda equina involvement: urinary hesitancy or retention; bowel incontinence, or severe constipation (erectile dysfunction insufficient on its own) (n = 39, 80%)		
A2. MRI or electrophysiologic evidence of cauda equina involvement: enhancement of cauda equina; EMG evidence of radiculopathy (n = 20, 41%)		
B. Supportive but not required		
B1. Time course: acute/subacute onset; no relapse; progression over less than 3 mo (n = 42, 86%)		
B2. Coexisting or recently preceding symptoms of genital herpes infection OR other clinical symptoms of herpes virus infection (n = 5, 10%)		
B3. Clinical (e.g., exaggerated reflexes and Babinski signs) or MRI evidence of myelitis in conus (n = 28, 57%)		
B4. CSF pleocytosis (n = 23, 47%)		
B5. Documented herpes virus infection from CSF by PCR, culture, or detection of IgM serology (n = 5, 10%)		
C. Red flags		
C1. Relapses beyond 1 y from onset (n = 4, 8%)		
D. Exclusionary		
D1. Myelitis extending rostral to T9 (n = 12, 25%)		
D2. Other neurologic symptoms suggestive of alternative etiology: optic neuritis, brain/brainstem syndrome (n = 3; 6%)		
D3. Other etiology proven/more likely for syndrome: NMO, dural arteriovenous fistula, viral transverse myelitis, other causes of myelopathy (n = 11, 22%)		

Abbreviations: IgM = immunoglobulin M; NMO = neuromyelitis optica spectrum disorder.

**Figure 1** Flow chart of patient selection



Interrogation of the electronic database for specific key terms highlighted in the first box returned a list of 1,035 patients. We excluded patients with an ICD code identifying NMO and MS, yielding 837 patients. Further interrogation of the database for patients with the following key terms returned 337 patients: "urinary retention" OR "paresthesia" OR "neuralgic pain" OR "constipation" OR "impotence" OR "perineal" OR "retention" OR "anus" OR "anal" OR "saddle". After the review of individual clinical records of the remaining patients, we excluded 213 subjects who had likely or established alternative diagnoses, as listed in the figure, and only patients who were confirmed to have urinary retention and other sacral sensory symptoms were retained. Of the remaining 49 patients, 19 did not satisfy any of the levels of diagnostic certainty proposed in table 1. The remaining 30 were assigned a specific diagnostic category according to the level of suspicion for ES. ES = Elsberg syndrome; ICD = *International Classification of Disease*; NMO = neuro-myelitis optica.

photophobia, diarrhea, myalgia, and general malaise. Sacral herpes infection (zoster, n = 1; simplex, n = 1) immediately preceded clinical presentation in 2 patients and oral herpes simplex in 1 patient. Urinary retention was present in 23 (77%) patients and

required indwelling catheterization in 21 (70%) patients. Saddle anesthesia (n = 15, 50%) and constipation (n = 13, 43%) were common. Fifteen (50%) patients had weakness of the lower limbs worse than 3/5 on the MRC scale in 7 patients (23%). Lower

**Table 2** Alternative diagnoses established or likely (213 patients)

Condition	No.
Spinal stenosis (intraspinal or extraspinal tumors, disk herniation, bone compression, trauma, ankylosing spondylitis, tuberculosis, osteomyelitis, or spinal abscess)	50
Vascular myelopathy (dural arteriovenous fistula, infarction)	41
Nonneurological	21
Peripheral nerve disorders: Guillain-Barré syndrome, chronic inflammatory demyelinating polyneuropathy, or others	19
MS or clinically isolated demyelinating syndrome	16
Myelitis secondary to systemic autoimmune diseases (sarcoidosis, SLE, Sjögren, Behçet, and systemic sclerosis)	14
NMO	11
Infectious myelitis: viral (not herpes!), bacterial, fungal, or parasitic.	10
Infectious brain infection (encephalitis or meningitis) or autoimmune CNS condition (neither MS nor NMO)	4
Neurodegenerative brain condition or movement disorder	4
Myofascial pain syndrome or fibromyalgia	4
Paraneoplastic myelitis	3
Primary bladder pathology	3
Motor neuron disease	3
Brain tumor or cord tumor (symptoms not due to compression)	3
Radiation myelopathy	2
Brain vascular event	2
Metabolic myelopathy (vitamins B12, D, E, and copper deficiencies)	1
Delirium	1
Restless leg syndrome	1

Abbreviations: NMO = neuromyelitis optica; SLE = systemic lupus erythematosus.

limb tendon reflexes were pathologically exaggerated in 10 patients (33%) and absent in 10 (33%); 4 (13%) had unequivocal and 6 (20%) patients had equivocal Babinski signs.

Eighteen patients (60%) were tested for viral infection, in particular for HSV ( $n = 16$ , 53%), varicella zoster virus (VZV) ( $n = 15$ , 50%), cytomegalovirus ( $n = 15$ , 50%), Epstein-Barr virus ( $n = 17$ , 57%), and HIV ( $n = 17$ , 57%). PCR confirmed viral infection in 3 patients (10%); in 2 patients, VZV was demonstrated in the CSF and, in 1 patient, HSV2 from a genital swab. Three patients were tested for Lyme disease, all with negative results. Radiculitis was confirmed in 21 patients (70%) by MRI with gadolinium ( $n = 17$ , 57%) or EMG ( $n = 12$ , 40%). MRI showed lumbar or lower thoracic cord T2-hyperintense signal abnormality in 18 patients

(60%) and cord gadolinium enhancement in 13 patients (43%). Sixteen patients (53%) had MRI evidence of concomitant myelitis and radiculitis (figure 2). Six patients (20%) had relatively minor MRI abnormalities within the spinal cord that extended rostral to T9–T10; in patients whose dominant cord lesion was caudal to T9, minor exceptions were allowed to the rule of excluding those with spinal cord abnormalities extending rostral to T9. Spinal cord lesions were multiple and discontinuous in 9 cases (30%) and were centrally or ventrally positioned within the cord. In 2 patients, the lesions were mildly expansile. In 3 cases (10%), the lesion was only present in the lower thoracic cord, not in the conus. Nerve root enhancement was always smooth rather than nodular, occasionally diffuse, and sometimes limited to ventral or dorsal roots. Thirteen patients (43%) had MRI evidence of nerve root thickening. Nerve root enhancement often occurred contemporaneously with spinal cord involvement; evaluation of MRI at multiple time points, when available, showed that in 3 cases (10%) root enhancement occurred at a later point of the illness as cord lesions were resolving.

The median CSF white blood cell count in the Elsberg group was 9; 15 (50%) patients had more than 5 leukocytes/ $\mu\text{L}$ ; the average percentage of lymphocytes was 69%; 2 patients had an average 65% mononuclear predominance. CSF proteins were consistently elevated (mean  $143 \pm 131$  mg/dL), whereas oligoclonal bands were rarely detected (table 3).

ES was considered in the differential diagnosis of 3 (10%) patients. Acyclovir was administered in 6 (20%) patients and corticosteroids in 15 (50%) patients, typically methylprednisolone 1 g per day over 3–5 days. Follow-up data were available for 13 (43%) patients (table 4). One patient (3%) died with encephalomyelitis and cardiac arrest; 3 patients (10%) had no neurologic recovery; 8 moderate recovery (27%); and 1 complete recovery (3%). Only 2 patients (7%) relapsed, one at 33 and the other at 82 months from onset.

**DISCUSSION** ES is poorly defined and rarely reported, but it is probably frequently unrecognized. Based on the historical literature and our clinical experience, we formulated objective criteria for ES with 4 different levels of certainty (table 1). Radiculitis, manifest either clinically (table 1, A1), radiologically or electrophysiologically (table 1, A2) is required. A secure diagnosis is possible when evidence for infection by a causative virus is demonstrated and alternative causes excluded, but given the sensitivity of the serologic and virologic studies<sup>9</sup> and frequent delay in obtaining appropriate samples, clinical and radiologic evidence may suggest ES regardless of the microbiologic information. For this reason,

**Table 3** Key clinical and radiologic features

Men/women	24/6
Median age at onset, y (range)	52.9 (10.7–82.7)
Herpes zoster immediately before episode, n (%)	0 (0.0)
Sacral herpes infection immediately before episode, n (%)	2 (6.7)
Herpes labialis immediately before episode, n (%)	1 (3.3)
Presence of prodromal symptoms, n (%) <sup>a</sup>	5 (16.7)
Urinary retention, n (%)	23 (76.7)
Catheter required for retention, n (%)	21 (70.0)
Urinary incontinence, n (%)	7 (23.3)
Bowel incontinence (%)	3 (10.0)
Saddle anesthesia, n (%)	15 (50.0)
Constipation, n (%)	13 (43.3)
Exaggerated/pathologic lower limb tendon reflexes, n (%)	10 (30.0)
Absent lower limb tendon reflexes, n (%)	10 (33.3)
Loss of limb sensation, n (%)	24 (80.0)
Leg weakness, n (%)	15 (50.0)
Leg weakness <3/5 (MRC scale), n (%)	7 (23.3)
Extensor plantar response, n (%)	4 (13.3)
Immunosuppression, n (%)	1 (3.3)
Patients tested for virus (either PCR or serology from CSF, serum, or genital swab), n (%)	18 (60.0)
PCR performed, n (%)	17 (56.7)
Patients with positive PCR, n	3 (10.0)
Median delay in CSF sample collection, d (range)	32 (1–443)
CSF obtained, n (%)	25 (83.3)
Median cell count in CSF/ $\mu$ L (range)	9 (0–1,057)
Patients with >5 nucleated cells/ $\mu$ L in CSF, n (%)	15 (50.0)
Mean percentage of lymphocytes in those with >5 WBC/ $\mu$ L (SD)	69 (24.0)
Patients with CSF pleocytosis and >5% neutrophils, n (%)	3 (20.0)
Median number of oligoclonal bands (range)	0 (0–7)
Mean CSF protein mg/dL (SD)	143 (131)
EMG evidence of radiculopathy, n (%)	12 (40.0)
MRI T2 cord hyperintensity in conus, n (%)	15 (50.0)
MRI T2 cord hyperintensity in lower thoracic cord (below T10), n (%)	18 (60.0)
MRI gadolinium enhancement (from T10), n (%)	13 (43.3)
MRI nerve root enhancement, n (%)	17 (56.7)
Root thickening in cauda, n (%)	13 (43.3)
Pial/subpial enhancement, n (%)	3 (10.0)
Thoracic or cervical MRI cord abnormal, n (%)	6 (20.0)

Abbreviation: WBC = white blood cell.

<sup>a</sup>Prodromal symptoms: fever; headache; myalgia; malaise; diarrhea; photophobia; lymphadenopathy.

we established criteria for clinically definite, probable, and possible ES (see supportive feature in table 1, B1–B5). In addition, we identified red flags that are cautionary but not exclusionary as well as exclusionary criteria (table 1, C and D).

The onset of ES was consistently acute in our cohort; insidious onset and evolution suggest alternative explanations such as sarcoidosis or neoplasm. Suspected cauda equina involvement, which leads to urinary retention, is confirmed with MRI and/or EMG. Concomitant myelitis detected radiologically or clinically further supports the diagnosis. Myelitis, associated with many inflammatory CNS conditions such as MS, NMO, anti-MOG antibody myelitis, sarcoidosis, and others, is not usually associated with radiculitis, whereas radiculitis is a required feature for the diagnosis of ES.

We did not identify pathognomonic or specific neuroradiologic findings. Nevertheless, some features were typical and could help distinguish ES from other disorders. Spinal cord lesions were commonly multiple and discontinuous, usually not expansile, and centrally or ventrally positioned in the cord. Unlike the imaging usual pattern of dural arteriovenous fistula, which can also cause both upper and lower motor neuron problems, the cord lesions in ES are not consistently located in the most caudal portion of the conus. Dural arteriovenous fistula lesions, in contradistinction to ES, are usually continuous, extending rostral from the lowermost portion of the conus, involve the most of the thickness of the cord, and are commonly associated with swelling. Nerve root enhancement was sometimes diffuse and sometimes limited to ventral or dorsal roots. It was always smooth and continuous and never nodular or plaque like as can be seen with neoplastic nerve root lesions.<sup>10</sup> Nerve root enhancement often occurred contemporaneously with spinal cord involvement, although either nerve root enhancement or spinal cord parenchymal signal abnormality could predominate; in some cases, root enhancement occurred at a later point of the illness as cord lesions were resolving. Finally, plaque or subpial cord enhancement, typical of granulomatous conditions,<sup>11</sup> did not occur in patients with ES.

CSF examination demonstrated lymphocytic pleocytosis in 15 patients (50%), and in 3 of those (20%), neutrophils exceeded 5%.

Although HSV infection is widely believed to be responsible for a majority of cases, almost half of the cases (13/30) were never investigated for the presence of a viral infection even though lumbar puncture was performed, indicative of the low level of diagnostic suspicion for an infectious etiology for this condition. Furthermore, when PCR was performed, only 2 of the 30 (7%) were positive in the CSF and 1 from a genital swab. Despite CSF viral detection being considered the diagnostic gold standard, its diagnostic accuracy is imperfect in real-life settings,<sup>9,12</sup> with a negative predictive value of 82% and a positive predictive value of 54% in one study.<sup>9</sup> Therefore,

**Table 4** Summary of treatments and clinical course

	Treatment with acyclovir	Treatment with corticosteroids	Both	Neither
Patients, n (%)	4 (13.3)	13 (43.3)	2 (6.7)	11 (36.7)
Patients with follow-up, n (%)	3 (10.0)	7 (23.3)	2 (6.7)	1 (3.3)
Patients with >6 mo follow-up, n (%)	2 (6.7)	7 (23.3)	2 (6.7)	1 (3.3)
Median follow-up (range), mo	23 (1-81)	92 (21-385)	101 (17-185)	261
Fatal outcome, n (%)	0	1 (3.3)	0	0
No recovery, n (%)	0	1 (3.3)	1 (3.3)	1 (3.3)
Partial recovery, n (%)	3 (10.0)	3 (10.0)	1 (3.3)	1 (3.3)
Complete recovery at follow-up, n (%)	0	1 (3.3)	0	0
Patients with relapses at follow-up, n (%)	0	2 (6.7)	0	0

a negative result cannot absolutely exclude the presence of infection. Furthermore, rapid viral clearance from the CSF has been shown for HSV and VZV infections.<sup>13</sup> The highest yield of viral detection by PCR occurred in samples obtained 3–14 days after symptom onset.<sup>9</sup> In our cohort, samples were acquired outside this interval in 14 of the 18 cases (78%); the only 2 positive CSF PCR samples were obtained at days 11 and 37. Of the 3 patients who experienced an HSV infection immediately preceding ES, only 1 (33%) was tested within 14 days and 1 at day 15; none were positive for HSV infection in the CSF and 1 tested positive only from a genital swab.

Reported experience with CSF PCR in patients with ES is mostly limited to case reports and sometimes other viral detection methods, such as serology or culture, have been used.<sup>5</sup> Antibody studies may be particularly useful when CSF is obtained late (e.g., >14 days) in the course of the disease. Demonstration of intrathecal production of HSV- or VZV-specific immunoglobulin G (IgG) antibodies can be diagnostic.<sup>14,15</sup> Reliance on an antibody index comparing virus-specific IgG levels in CSF and serum with correction for blood-brain barrier leak using either the CSF/serum albumin ratio or the ratio of CSF/serum antibody titers of a nonpathogenic virus ensures that serum HSV or VZV antibodies have not reached the CSF by means of a sink mechanism. Although rarely demonstrated, the presence of virus-specific immunoglobulin M (IgM) in the CSF is strongly indicative of acute or active chronic CNS infection as these antibodies do not tend to cross the blood-brain barrier.

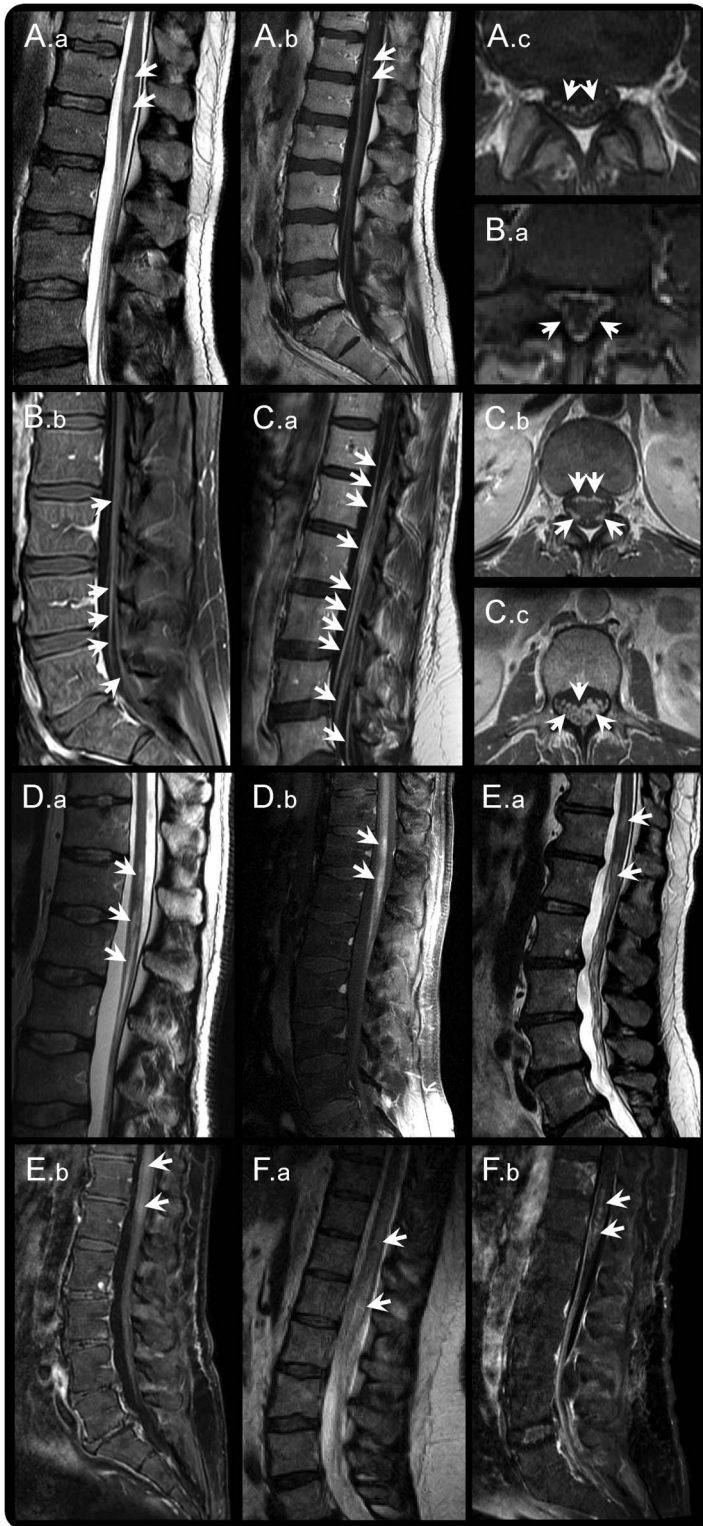
The 2 patients with a positive CSF PCR were positive for VZV. VZV may be considered an etiologic agent of ES,<sup>1</sup> but is also recognized to be a cause of myelitis and/or myeloradiculitis occurring elsewhere in the spinal cord. The 2 patients with herpes zoster detection experienced more widespread involvement of the spinal cord than did other Elsberg cases. The

first patient, who was immunocompetent, had a few discrete lesions higher in the cord and also had encephalitic manifestations; the second patient, who was HIV positive and immunocompromised, had a longitudinally extensive lesion spanning up to 9 vertebral segments of the thoracic spine and had evidence of meningeal irritation and necrotic cord damage. Ascending necrotic myelitis has been described in the setting of HSV2.<sup>16</sup> Although the patients with VZV meet the criteria for ES, encephalitic symptoms as well as long thoracic and cervical cord MRI lesions and meningeal irritation may be considered red flags, and caution in the diagnostic process should be maintained before providing a final diagnosis.

HSV and VZV are treatable when acyclovir is initiated early, but the potential benefits of treatments with antiviral drugs have not been documented. In our cohort, none of the 5 patients with follow-up who received acyclovir experienced a fatal outcome. Yet, one patient treated with both acyclovir and corticosteroids had no clinical recovery as did one patient who received corticosteroid treatment alone and another who received neither (table 4). Therefore, superiority of acyclovir treatment cannot be proven. Nonetheless, acyclovir treatment was started only in 6 patients, whereas high-dose corticosteroids were administered as primary treatment in 15 patients, illustrating the low index of suspicion for this condition and the tendency to treat as an idiopathic inflammatory condition.

The study is limited by its retrospective nature. Because of the referral pattern of patients to our institution, patients were evaluated initially at outside institutions and as this study was retrospective, investigations were not standardized. Potentially, we did not capture all cases by our electronic search strategy. The proportion of laboratory-supported definite cases and of patients with proven HSV infection was low. This might reflect low rates of awareness of this syndrome and consequent low proportion of cases

**Figure 2** MRI evidence of myelitis and radiculitis in 6 patients



Patient A presents with concomitant presence of multiple and discontinuous T2 hyperintense lesions (A.a) that enhance on T1-weighted images after gadolinium injection (A.b) concomitantly with nerve roots of the cauda equina (A.b and A.c). Nerve root enhancement is prominent in 2 other patients (B.a, B.b, C.a, and C.b), with greater nerve root thickening in the latter (C.c). Two other patients had multifocal, discontinuous, T2-hyperintense lesions (D.a and E.a) as well as enhancement (D.b and E.b) in both the conus and lower thoracic cord. Finally, cord T2-hyperintense abnormality (F.a) may precede the onset of nerve root enhancement (F.b) by 26 days.

with acute and convalescent serology results. Limitations of sensitivity of viral isolation methods particularly when samples are obtained late in the course may be an additional contributor. Perhaps, next-generation sequencing may enhance diagnostic sensitivity as already shown with other infections.<sup>17</sup>

We recognize that the scientific literature is moving away from eponymous definitions. Our intent was not to entrench an eponymous definition, but to formalize diagnostic criteria that are flexible to aid in the identification of patients with combinations of radiculitis and caudal myelitis who have potentially treatable viral infections after considering clinical and radiologic clues that identify other potential etiologies for this syndrome. Improved testing and virus identification methodologies may establish the role of antiviral treatment.

ES is a definable condition that may be responsible for approximately 5%–15% of patients with CES and myelitis based on our review of cases seen at the Mayo Clinic. It is usually self-limited but commonly leaves some degree of permanent neurologic deficit and in one instance led to a fatal outcome. Although radiologic findings are not specific, they can help to rule out competing diagnoses, such as dural arteriovenous fistula, sarcoidosis, and other conditions. When both enhancement of cauda equina and signal abnormality of the distal spinal cord occur acutely, Elsberg may be a common cause of the syndrome. The diagnostic criteria that we formulated may bring attention to this condition and permit a more precise diagnosis when integrated with tests to exclude other mimics. Detection of viral infection is useful, but sensitivity appears to be low. Treatment with acyclovir is appropriate even in the absence of demonstration of viral infection given the favorable risk-benefit profile of this drug.

#### AUTHOR CONTRIBUTIONS

Brian G. Weinschenker conceived the idea for the manuscript, reviewed and interpreted source data, and oversaw all aspects of the project. Filippo Savoldi collected and interpreted data and drafted the manuscript. Timothy J. Kaufmann reviewed MRI scans of all patients suspected to have Elsberg syndrome. All authors revised the manuscript critically for important intellectual content and provided final approval of the version to be published.

#### STUDY FUNDING

No targeted funding reported.

#### DISCLOSURE

F. Savoldi reports no disclosures. T.J. Kaufmann served on the editorial board for *American Journal of Neuroradiology* and *Neuro-Oncology*; consulted for SpinThera; and received research support from the National Cancer Institute. E.P. Flanagan and M. Toledano report no disclosures. B.G. Weinschenker served on the data safety monitoring board for Novartis, Biogen, and Mitsubishi; served on the editorial board for *Canadian Journal of Neurological Sciences*, *Turkish Journal of Neurology*, and *Neurology*<sup>®</sup>; holds a patent for and receives royalties from NMO-IgG for the diagnosis of neuromyelitis optica; consulted for Caladrius; and

served as an adjudication committee member for MedImmune and Alexion. Go to [Neurology.org/nn](http://Neurology.org/nn) for full disclosure forms.

Received March 5, 2017. Accepted in final form April 5, 2017.

## REFERENCES

1. Eberhardt O, Kuker W, Dichgans J, Weller M. HSV-2 sacral radiculitis (Elsberg syndrome). *Neurology* 2004;63:758–759.
2. Caplan LR, Kleeman FJ, Berg S. Urinary retention probably secondary to herpes genitalis. *N Engl J Med* 1977;297:920–921.
3. Hemrika DJ, Schutte MF, Bleker OP. Elsberg syndrome: a neurologic basis for acute urinary retention in patients with genital herpes. *Obstet Gynecol* 1986;68:37S–39S.
4. Nakajima H, Furutama D, Kimura F, et al. Herpes simplex virus myelitis: clinical manifestations and diagnosis by the polymerase chain reaction method. *Eur Neurol* 1998;39:163–167.
5. Suarez-Calvet M, Rojas-Garcia R, Querol L, Sarmiento LM, Domingo P. Polyradiculoneuropathy associated to human herpesvirus 2 in an HIV-1-infected patient (Elsberg syndrome): case report and literature review. *Sex Transm Dis* 2010;37:123–125.
6. Aurelius E, Forsgren M, Gille E, Skoldenberg B. Neurologic morbidity after herpes simplex virus type 2 meningitis: a retrospective study of 40 patients. *Scand J Infect Dis* 2002;34:278–283.
7. Yoritaka A, Ohta K, Kishida S. Herpetic lumbosacral radiculoneuropathy in patients with human immunodeficiency virus infection. *Eur Neurol* 2005;53:179–181.
8. Oates JK, Greenhouse PR. Retention of urine in anogenital herpetic infection. *Lancet* 1978;1:691–692.
9. Davies NW, Brown LJ, Gonde J, et al. Factors influencing PCR detection of viruses in cerebrospinal fluid of patients with suspected CNS infections. *J Neurol Neurosurg Psychiatry* 2005;76:82–87.
10. Smith JK, Lury K, Castillo M. Imaging of spinal and spinal cord tumors. *Semin Roentgenol* 2006;41:274–293.
11. Smith JK, Matheus MG, Castillo M. Imaging manifestations of neurosarcoidosis. *AJR Am J Roentgenol* 2004;182:289–295.
12. Jeffery KJM, Read SJ, Peto TEA, Mayon-White RT, Bangham CRM. Diagnosis of viral infections of the central nervous system: clinical interpretation of PCR results. *Lancet* 1997;349:313–317.
13. Kleines M, Scheithauer S, Schiefer J, Hausler M. Clinical application of viral cerebrospinal fluid PCR testing for diagnosis of central nervous system disorders: a retrospective 11-year experience. *Diagn Microbiol Infect Dis* 2014;80:207–215.
14. Gobbi C, Tosi C, Städler C, Merenda C, Bernasconi E. Recurrent myelitis associated with herpes simplex virus type 2. *Eur Neurol* 2001;46:215–218.
15. Takahashi T, Tamura M, Miki K, et al. Varicella zoster virus myelitis in two elderly patients: diagnostic value of nested polymerase chain reaction assay and antibody index for cerebrospinal fluid specimens. *Case Rep Neurol* 2013;5:81–90.
16. Wiley CA, VanPatten PD, Carpenter PM, Powell HC, Thal LJ. Acute ascending necrotizing myelopathy caused by herpes simplex virus type 2. *Neurology* 1987;37:1791–1794.
17. Wilson MR, Naccache SN, Samayoa E, et al. Actionable diagnosis of neuroleptospirosis by next-generation sequencing. *N Engl J Med* 2014;370:2408–2417.



# Neurology<sup>®</sup> Neuroimmunology & Neuroinflammation

## Elsberg syndrome: A rarely recognized cause of cauda equina syndrome and lower thoracic myelitis

Filippo Savoldi, Timothy J. Kaufmann, Eoin P. Flanagan, et al.  
*Neurol Neuroimmunol Neuroinflamm* 2017;4;  
DOI 10.1212/NXI.0000000000000355

This information is current as of May 11, 2017

<b>Updated Information &amp; Services</b>	including high resolution figures, can be found at: <a href="http://nn.neurology.org/content/4/4/e355.full.html">http://nn.neurology.org/content/4/4/e355.full.html</a>
<b>References</b>	This article cites 17 articles, 1 of which you can access for free at: <a href="http://nn.neurology.org/content/4/4/e355.full.html##ref-list-1">http://nn.neurology.org/content/4/4/e355.full.html##ref-list-1</a>
<b>Subspecialty Collections</b>	This article, along with others on similar topics, appears in the following collection(s): <b>MRI</b> <a href="http://nn.neurology.org/cgi/collection/mri">http://nn.neurology.org/cgi/collection/mri</a> <b>Transverse myelitis</b> <a href="http://nn.neurology.org/cgi/collection/transverse_myelitis">http://nn.neurology.org/cgi/collection/transverse_myelitis</a> <b>Viral infections</b> <a href="http://nn.neurology.org/cgi/collection/viral_infections">http://nn.neurology.org/cgi/collection/viral_infections</a>
<b>Permissions &amp; Licensing</b>	Information about reproducing this article in parts (figures, tables) or in its entirety can be found online at: <a href="http://nn.neurology.org/misc/about.xhtml#permissions">http://nn.neurology.org/misc/about.xhtml#permissions</a>
<b>Reprints</b>	Information about ordering reprints can be found online: <a href="http://nn.neurology.org/misc/addr.xhtml#reprintsus">http://nn.neurology.org/misc/addr.xhtml#reprintsus</a>

*Neurol Neuroimmunol Neuroinflamm* is an official journal of the American Academy of Neurology. Published since April 2014, it is an open-access, online-only, continuous publication journal. Copyright © 2017 The Author(s). Published by Wolters Kluwer Health, Inc. on behalf of the American Academy of Neurology. All rights reserved. Online ISSN: 2332-7812.

