

Andreia Costa, MD, MSc*
 André Silva-Pinto, MD, MSc*
 Joana Alves, MD, MSc
 Nélia Neves, MD, MSc
 Eugenia Martínez-Hernández, MD, PhD
 Pedro Abreu, MD
 António Sarmiento, MD, PhD

Neurol Neuroimmunol Neuroinflamm
 2017;4:e392; doi: 10.1212/
 NXI.0000000000000392

POSTMALARIA NEUROLOGIC SYNDROME ASSOCIATED WITH NEUREXIN-3 α ANTIBODIES

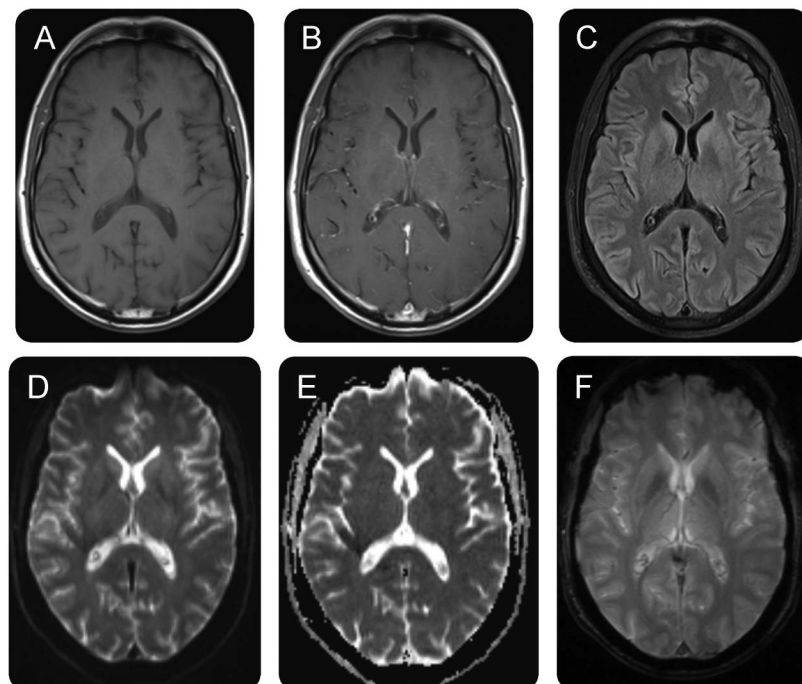
OPEN

A 57-year-old Caucasian man with no clinical history of interest returned to Portugal after a long stay in rural Angola. Fifteen days before returning to Portugal, he had visited a tropical forest region in the North of Angola. Five days after returning, he experienced fever, asthenia, dizziness, and myalgia. He was diagnosed with *Plasmodium falciparum* malaria (8% parasitemia), with no severity criteria according to the World Health Organization guidelines.¹ He was successfully treated with IV quinine-doxycycline and discharged home 11 days after fully recovered.

Two weeks later, the patient developed fever, apathy, somnolence, sleep-awake cycle disruption, confusion, and altered behavior, progressing for 7 days. On examination, he was febrile but hemodynamically stable. A mild macular rash in the trunk and

a nonpainful, nontender mass in the posterior cervical region were noted. He was disoriented in time and space, had severe attention deficit, acalculia, and visuospatial difficulties. Blood laboratory tests showed mild hypochromic anemia, with no further abnormalities. No *Plasmodium* parasites were found in the thin blood smear. Brain CT was normal, and the CSF study showed 159 cells (91% mononuclear), protein 2.12 g/dL, normal glucose CSF/serum ratio, and normal IgG index. EEG was consistent with a severe subcortical encephalopathy with no epileptic activity. Brain MRI showed a mild increase of T2/fluid-attenuated inversion recovery signal in the caudate-capsule-lenticulate regions with no gadolinium enhancement (figure). Extensive serum and CSF studies were negative for active infectious (table) or systemic autoimmune causes (negative antinuclear antibodies, anti-neutrophil cytoplasmic antibodies, anti-double-strand DNA, anti-extractable nuclear antigens, rheumatoid factor, anti-amphiphysin 1,

Figure Brain MRI



Mild increase of T2/fluid-attenuated inversion recovery (FLAIR) signal in the caudate-capsule-lenticulate regions with no gadolinium enhancement. (A) T1, (B) T1 with gadolinium, (C) T2 FLAIR, (D) diffusion-weighted image, (E) apparent diffusion coefficient, and (F) gradient echo.

Table Infectious studies					
Test	IgM	IgG	Blood	CSF	Cervical lymph node
Culture					
Bacterial			-(x2)	-	-
Fungal				-	
Serology					
<i>Borrelia afzelii</i> and <i>garinii</i>	-	-			
CMV	+	+			
EBV	-	+			
HSV1	-	+			
HSV2	+	+			
<i>Mycoplasma</i> species	-	-			
<i>Rickettsia conorii</i>		-			
TPPA	-				
<i>Trypanosoma brucei gambiense</i> ^a	-				
Wright reaction	-				
Nucleic acid amplification test					
CMV				-	
Enterovirus				-	
HSV				-	
<i>Tropheryma whipplei</i>				-	
<i>Trypanosoma</i> species ^a			-	-	-
VZV				-	
West Nile virus				-	
Direct identification					
<i>Plasmodium</i> species (thin blood smear)			-(x3)		
<i>Trypanosoma</i> species ^a			-	-	-

Abbreviations: CMV = cytomegalovirus; EBV = Epstein-Barr virus; HSV = herpes simplex virus; TPPA = *Treponema pallidum* particle agglutination enzyme immunoassay; VZV = varicella zoster virus.

^a Performed in the national reference laboratory for *Trypanosoma* species (Instituto de Higiene e Medicina Tropical, Universidade Nova de Lisboa, Lisboa, Portugal).

anti-CV2/CRMP5, anti-Ma2, anti-Ri, anti-Yo, and anti-Hu antibodies in serum).

Neurologic symptoms progressed for the next 8 days, and postmalaria neurologic syndrome (PMNS) was diagnosed. A 5-day course of 1 g IV methylprednisolone resulted in a significant clinical improvement. A follow-up CSF study showed 34 cells, protein 1.7 g/dL, normal glucose CSF/serum ratio, and no oligoclonal bands. The patient was discharged on day 15, asymptomatic. Patient samples were sent to a neuroimmunology referral center (Professor Josep Dalmau Laboratory, Neuroimmunology, IDIBAPS, Barcelona, Spain), which showed the presence of neurexin-3 α antibodies.² The presence of cell surface/synaptic neuronal antibodies was determined by rat brain immunohistochemistry, which showed a distinctive pattern of serum and CSF reactivity with

neuropil of rat brain that was different from other previously known antibodies, and by specific cell-based assays, which confirmed positive serum and CSF reactivity with human embryonic kidney 293 (HEK293)-expressing neurexin-3 α , and negative reactivity with HEK293 expressing the NMDA, AMPA, GABA-A, GABA-B, mGluR1, and mGluR5 receptors, or LGI1, Caspr2, DPPX, and IgLON5 proteins.

A new form of autoimmune encephalitis associated with neurexin-3 α antibodies was recently described in 5 patients.² One of them may have had a history of malaria a few months before developing autoimmune encephalitis (patient 1 of Gresa-Arribas et al.²). This patient, a 23-year-old Caucasian woman, presented with a 2-week history of worsening headache, somnolence, disorientation, confusion, and recent memory problems. Two months before, she had returned from a 6-month trip to Tanzania. During her stay in a rural area in Tanzania, she had 2 episodes of fever which had been treated as malaria (despite no microbiologic confirmation). On admission, she was disoriented in time and space, with emotional lability, short-term memory deficits, and confabulations. Blood smear test was negative for parasites. Transient leukopenia and thrombocytopenia were detected in blood tests. CSF showed 20 cells with normal protein and glucose; brain MRI was normal; and EEG showed slow activity on left posterior temporal areas. Extensive microbiologic studies were negative in blood and CSF. She was treated with IV methylprednisolone with improvement.

We report here another patient whose neurologic symptoms were confirmed preceded by malaria and who had a rapid improvement after steroid treatment.

PMNS was first described, mainly in adults after recovery of severe falciparum malaria, in 1996 in Vietnam.³ There are some previous descriptions of delayed cerebellar ataxia following malaria in India and Sri Lanka.^{4,5} The clinical picture of PMNS is characterized by neuropsychiatric manifestations, including confusion, altered behavior, decreased consciousness, hallucinations, and seizures. The neurologic syndrome is self-limited, and no specific treatment is required, although in severe cases steroids may be beneficial.⁶ Immune-mediated mechanisms have been postulated in this postinfectious diffuse encephalopathy, but no autoantibodies had been previously reported.

The case reported here suggests that encephalitis associated with neurexin-3 α antibodies can potentially manifest as postinfectious encephalitis. Recognition of this disorder is important because it responds to immunotherapy. Similar investigations are worth to consider in patients with malaria and

especially in patients with PMNS to further elucidate the relationship between these entities.

*These authors contributed equally to the manuscript.

From the Department of Neurology (A.C., P.A.), Department of Infectious Diseases (A.S.-P., J.A., N.N., A.S.), Centro Hospitalar São João, Porto, Portugal; Department of Neuroscience and Mental Health (A.C., P.A.), Faculty of Medicine of University of Porto, Portugal; Nephrology and Infectious Diseases R&D Group (A.S.-P., J.A., N.N., A.S.), Health Investigation and Innovation Institute (I3S), University of Porto, Portugal; and Neuroimmunology Program (E.M.-H.), Institut d'Investigacions Biomèdiques August Pi i Sunyer (IDIBAPS), Barcelona, Spain.

Author contributions: A. Costa and A. Silva-Pinto: clinical management of the patient, description of the clinical case, and elaboration of the manuscript. J. Alves: clinical management of the patient, especially regarding *Trypanosoma* exclusion, and revision of the manuscript. N. Neves: clinical management of the patient and revision of the manuscript. E. Martínez-Hernández: laboratorial workout, description of the laboratorial techniques, and revision of the manuscript. P. Abreu and A. Sarmento: study concept and critical revision of the manuscript for intellectual content.

Acknowledgment: The authors thank Professor Josep Dalmau for the scientific contribution to the manuscript.

Study funding: This study was not funded.

Disclosure: A. Costa, A. Silva-Pinto, J. Alves, and N. Neves report no disclosures. E. Martínez-Hernández received research support from Instituto de Salud Carlos III. P. Abreu received speaker honoraria from Biogen, Bayer, Novartis, Sanofi Genzyme, Merck Serono, and Boehringer Ingelheim and consulted for Biogen and Bayer. A. Sarmento reports no

disclosures. Go to Neurology.org/jn for full disclosure forms. The Article Processing Charge was funded by the authors.

This is an open access article distributed under the terms of the Creative Commons Attribution-NonCommercial-NoDerivatives License 4.0 (CC BY-NC-ND), which permits downloading and sharing the work provided it is properly cited. The work cannot be changed in any way or used commercially without permission from the journal.

Received April 7, 2017. Accepted in final form July 3, 2017.

Correspondence to Dr. Costa: andreaifcosta@gmail.com

1. Guidelines for the Treatment of Malaria, 3rd ed. World Health Organization: Geneva; 2015.
2. Gresa-Arribas N, Planaguma J, Petit-Pedrol M, et al. Human neuroligin-3 antibodies associate with encephalitis and alter synapse development. *Neurology* 2016;86:2235–2242.
3. Nguyen TH, Day NP, Ly VC, et al. Post-malaria neurological syndrome. *Lancet* 1996;348:917–921.
4. Senanayake N, de Silva HJ. Delayed cerebellar ataxia complicating falciparum malaria: a clinical study of 74 patients. *J Neurol* 1994;241:456–459.
5. Kochar DK, Kumawat BL, Kochar SK, Bajjiya HN, Maurya RK. Delayed cerebellar ataxia—a complication of *Plasmodium falciparum* malaria. *J Assoc Physicians India* 1996;44: 686–688.
6. Markley JD, Edmond MB. Post-malaria neurological syndrome: a case report and review of the literature. *J Trav Med* 2009;16:424–430.