

Neuroparacoccidioidomycosis

Euripedes Gomes Carvalho Neto, MD, Aline Coletto, MD, Paula Ghidini Biazus, MD, Iuri Pereira dos Santos, MD, Carlos R.M. Rieder, MD, PhD, and Marlise de Castro Ribeiro, MD, PhD

Correspondence

Dr. Carvalho Neto
euripedescneto@gmail.com

Neurol Neuroimmunol Neuroinflamm 2019;6:e519. doi:10.1212/NXL.0000000000000519

Paracoccidioidomycosis (PCM) is a human systemic mycosis caused by *Paracoccidioides brasiliensis*, a thermodynamically dimorphic fungus that causes a chronic granulomatous inflammatory disease.¹ It is an endemic disease in Latin America, with a higher incidence in Brazil.² In this article, we present the case of a patient with chronic multifocal PCM with CNS involvement.

Case report

A 47-year-old woman presented to our service with a high-intensity, throbbing holocranial headache, accompanied by nausea, vomiting, and dizziness for 2 months. The patient worked as a maid, and her medical history was significant only for tobacco use. Neurologic examination revealed dysphonia, dysmetria on the right, bilateral intention tremor, and mild gait ataxia. MRI scan of the brain showed intra-axial lesions in the cerebellar hemispheres, with peripheral enhancement by the contrast agent and adjacent vasogenic edema (figure 1). Due to the initial hypothesis of tumor lesion, the patient underwent chest tomography that showed nodular and excavated lesions compatible with a granulomatous infectious process (figure 2A). The nasofibrolaryngoscopy (performed due to the presence of dysphonia) evidenced edema of the posterior larynx and infiltrative lesions of both vocal cords, with subglottic extension to the left, which was biopsied (figure 2B). Both bronchoalveolar lavage and vocal cord biopsy were compatible with PCM, showing in Gomori-Grocott staining (silver) the presence of yeast elements of various sizes, compatible with *Paracoccidioides* sp. CSF examination was not performed due to contraindication to lumbar puncture due to edema in the posterior fossa. The patient received parenteral treatment with amphotericin B for 14 days and also dexamethasone, which was used for 6 days and then rapidly tapered off until complete cessation 7 days later, presenting clinical improvement and resolution of headache. She was discharged with sulfamethoxazole-trimethoprim (SMX-TMP) with the orientation of maintaining the treatment for at least 18 months. Currently, the patient is undergoing an outpatient follow-up and is awaiting the performance of control image examinations.

Discussion

The major risk factor for acquiring infection is a profession or activity related to the management of soil contaminated with the fungus, and unlike other mycoses (such as cryptococcosis, disseminated histoplasmosis, and candidiasis), it is not usually related to immunosuppressive diseases.³ PCM occurs more frequently in adults between the ages of 30 and 50 years, as a result of endogenous latent foci reactivation.⁴

Treatment for severe and disseminated forms of PCM, as in the case of our patient that had CNS involvement, amphotericin B in deoxycholate or in lipid formulation is indicated for use

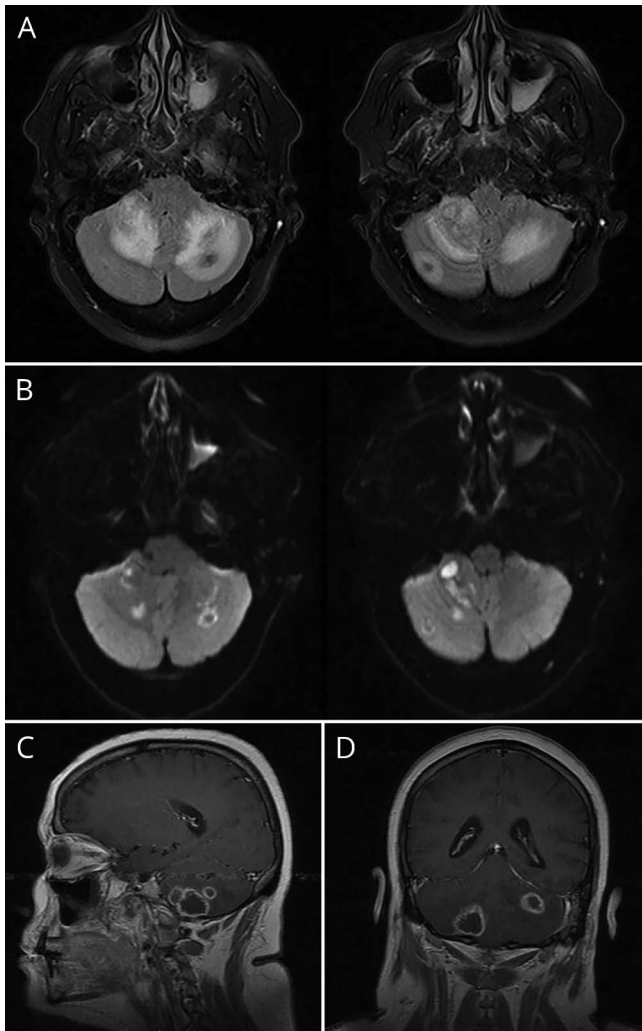
From the Irmandade Santa Casa de Misericórdia de Porto Alegre, Universidade Federal de Ciências da Saúde de Porto Alegre (E.G.C.N., A.C., P.G.B., I.P.d.S.); Movement Disorders Division, Irmandade Santa Casa de Misericórdia de Porto Alegre, Universidade Federal de Ciências da Saúde de Porto Alegre (C.R.M.R.); and Neuroimmunology Division, Irmandade Santa Casa de Misericórdia de Porto Alegre, Universidade Federal de Ciências da Saúde de Porto Alegre (M.d.C.R.).

Funding information and disclosures are provided at the end of the article. Full disclosure form information provided by the authors is available with the full text of this article at Neurology.org/NN.

The Article Processing Charge was funded by the authors.

This is an open access article distributed under the terms of the Creative Commons Attribution-NonCommercial-NoDerivatives License 4.0 (CC BY-NC-ND), which permits downloading and sharing the work provided it is properly cited. The work cannot be changed in any way or used commercially without permission from the journal.

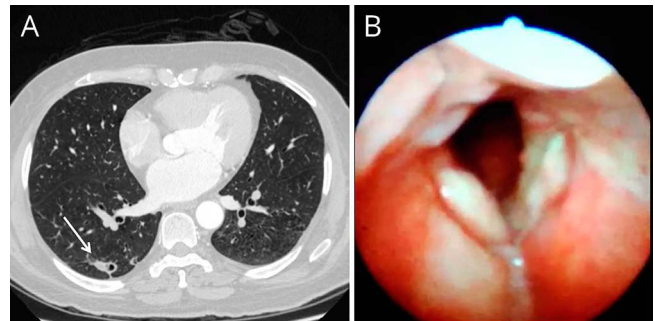
Figure 1 Brain MRI



(A) Axial fluid-attenuated inversion-recovery images show perilesional edema in both cerebellar hemisphere and hypointense in the center of the lesions. (B) Axial diffusion-weighted image sequences show hyperintense and hypointense lesions with restricted diffusion of water molecules. Sagittal (C) and Coronal (D) T1-weighted sequences show peripheral hyperintense rim surrounding a hypointense center and ring enhancement after intravenous infusion of paramagnetic contrast.

(induction phase). The duration of this phase depends on the clinical stability of the patient, and amphotericin B should be administered for the shortest possible time (on average 2–4 weeks).³ Transition to oral medication (consolidation phase) should occur after clinical stabilization, and SMX-TMP has been used because of its better posology and patients' adherence.⁵ The association of fluconazole with SMX-TMP also appears to be a viable option in the treatment of patients with neuroparacoccidioidomycosis.⁶ There is scarce evidence in the literature that some cases may benefit from the use of corticosteroids concomitant with antifungal treatment. The major concern in the treatment of severe forms of PCM is the intense inflammatory response induced by *P. brasiliensis*, which can be intensified by the antifungal therapy and, depending on the localization, as in

Figure 2 Chest CT and nasofibrolaryngoscopy findings



(A) CT of the thorax showed 3 nodular and micronodular lesions in the upper segment, one of the lesions with excavation, suggesting a granulomatous infectious process. (B) Nasofibrolaryngoscopy showing posterior laryngeal edema. Infiltrative lesions of both vocal folds with subglottic extension to the left, whose biopsy was compatible with paracoccidioidomycosis.

patients with CNS involvement, might be life-threatening.⁷ For this reason, we decide to add dexamethasone to the antifungal therapy.

After treatment and the observation of cure criteria, patients should undergo outpatient follow-up. However, the term definitive cure can never be applied to patients with PCM because *P. brasiliensis* cannot be eradicated from the organism. Therefore, the aim PCM treatment is to reduce the fungal load in the patient's body, allowing cellular immunity and the balance between parasite and host to recover.³

Conclusion

The differential diagnoses for neuroparacoccidioidomycosis usually include the following conditions: tuberculosis, cryptococcosis, cysticercosis, and neoplasias.³ In endemic areas, this diagnosis should be considered when ring-enhancing mass associated with perilesional edema is observed on MRI.^{8,9} In addition, considering a world that is getting smaller with emphasis on a global viewpoint, this diagnosis should be remembered when there is a compatible epidemiologic history.

Author contributions

E.G. Carvalho Neto: acquisition of data, literature review. A. Coletto: acquisition of data, literature review. P.G. Biazus: acquisition of data, literature review. I. Pereira dos Santos: acquisition of data, literature review. C.R.M. Rieder: critical revision of manuscript for intellectual content, study supervision. M. de Castro Ribeiro: critical revision of manuscript for intellectual content, study supervision.

Study funding

No targeted funding reported.

Disclosure

E.G. Carvalho Neto, A. Coletto, P.G. Biazus, and I. Pereira dos Santos report no disclosures; C.R.M. Rieder served as associate editor and editorial board member for *Arquivos Brasileiros de Neuropsiquiatria*; M. de Castro Ribeiro reports no disclosures. Full disclosure form information provided by the authors is available with the full text of this article at Neurology.org/NN.

Received April 16, 2018. Accepted in final form October 2, 2018.

References

1. Ramos-E-Silva M, Saraiva LdoE. Paracoccidioidomycosis. *Dermatol Clin* 2008;26:257-269.
2. Parise-Fortes MR, Miot HA, Kurokawa CS, Marques MEA, Marques AS. Imunologia da paracoccidioidomicose. *Bras Dermatol* 2011;86:516-525.
3. Shikanai-Yasuda MA, Mendes RP, Colombo AL, et al. Brazilian guidelines for the clinical management of paracoccidioidomycosis. *Rev Soc Bras Med Trop* 2017;50:715-740.
4. Wanke B, Londero AT. Epidemiology and paracoccidioidomycosis infection. In: Franco MF, Lacaz CS, Restrepo-Moreno A, Del Negro G, editors. *Paracoccidioidomycosis*. Boca Raton: CRC Press; 1994:109-120.
5. Shikanai-Yasuda MA. Paracoccidioidomycosis treatment. *Rev Inst Med Trop* 2015;57(suppl 19):31-37.
6. Francesconi F, da Silva MT, Costa RL, et al. Long-term outcome of neuro-paracoccidioidomycosis treatment. *Rev Soc Bras Med Trop* 2011;44:22-25.
7. Benard G, Campos AF, Netto LC, et al. Treatment of severe forms of paracoccidioidomycosis: is there a role for corticosteroids? *Med Mycol* 2012;50:641-648.
8. Isolan GR, Vieira DM, Hehn F, Antunes AC. Paracoccidioidomycosis simulating brain tumor. *Surg Neurol Int* 2014;5:134.
9. de Almeida SM, Queiroz-Telles F, Teive HA, Ribeiro CE, Werneck LC. Central nervous system paracoccidioidomycosis: clinical features and laboratorial findings. *J Infect* 2004;48:193-198.

Neurology[®] Neuroimmunology & Neuroinflammation

Neuroparacoccidioidomycosis

Euripedes Gomes Carvalho Neto, Aline Coletto, Paula Ghidini Biazus, et al.

Neurol Neuroimmunol Neuroinflamm 2019;6;

DOI 10.1212/NXI.0000000000000519

This information is current as of November 7, 2018

Updated Information & Services	including high resolution figures, can be found at: http://nn.neurology.org/content/6/1/e519.full.html
References	This article cites 8 articles, 0 of which you can access for free at: http://nn.neurology.org/content/6/1/e519.full.html##ref-list-1
Subspecialty Collections	This article, along with others on similar topics, appears in the following collection(s): All Clinical Neurology http://nn.neurology.org/cgi/collection/all_clinical_neurology All Infections http://nn.neurology.org/cgi/collection/all_infections Fungal infections http://nn.neurology.org/cgi/collection/fungal_infections MRI http://nn.neurology.org/cgi/collection/mri
Permissions & Licensing	Information about reproducing this article in parts (figures, tables) or in its entirety can be found online at: http://nn.neurology.org/misc/about.xhtml#permissions
Reprints	Information about ordering reprints can be found online: http://nn.neurology.org/misc/addir.xhtml#reprintsus

Neurol Neuroimmunol Neuroinflamm is an official journal of the American Academy of Neurology. Published since April 2014, it is an open-access, online-only, continuous publication journal. Copyright Copyright © 2018 The Author(s). Published by Wolters Kluwer Health, Inc. on behalf of the American Academy of Neurology. All rights reserved. Online ISSN: 2332-7812.

