

# Anti-MOG encephalitis mimicking small vessel CNS vasculitis

Kristina Patterson, MD, PhD, Estibaliz Iglesias, MD, PhD, Maclean Nasrallah, MD, PhD, Verónica González-Álvarez, MD, Mariona Suñol, MD, Jordi Anton, MD, PhD, Albert Saiz, MD, PhD, Eric Lancaster, MD, PhD, and Thais Armangue, MD, PhD

**Correspondence**  
Dr. Armangue  
armangue@clinic.cat

*Neurol Neuroimmunol Neuroinflamm* 2019;6:e538. doi:10.1212/NXI.0000000000000538

## Abstract

### Objective

To report 2 patients with anti-myelin oligodendrocyte glycoprotein (MOG)-associated encephalitis who were initially misdiagnosed with small vessel primary CNS vasculitis.

### Methods

Review of symptoms, MRI and neuropathologic features, and response to treatment. MOG antibodies were determined in serum and CSF using a cell-based assay.

### Results

Symptoms included fever, headache, and progressive mental status changes and focal neurologic deficits. CSF studies revealed lymphocytic pleocytosis, and both patients had abnormal brain MRIs. Brain biopsy samples showed prominent lymphocytic infiltration of the wall of small vessels; these findings initially suggested small vessel CNS vasculitis, and both patients were treated accordingly. Although 1 patient had a relapsing-remitting course not responsive to cyclophosphamide, the other one (also treated with cyclophosphamide) did not relapse. Retrospective assessment of serum and CSF demonstrated MOG antibodies in both cases, and review of biopsy specimens showed absence of fibrinoid necrosis (a pathologic requirement for small vessel CNS vasculitis).

### Conclusions

Anti-MOG-associated encephalitis can be mistaken for small vessel CNS vasculitis. This is important because the diagnosis of anti-MOG-associated encephalitis does not require brain biopsy and can be established with a serologic test.

## RELATED ARTICLE

### Editorial

Diagnostic challenges and pitfalls of myelin oligodendrocyte glycoprotein antibody-associated demyelination: Lessons from neuropathology

Page e544

From the Neurology Department (K.P., E.L.), University of Pennsylvania, Philadelphia; Rheumatology Department, Sant Joan de Deu Children's Hospital (E.I., J.A.), University of Barcelona, Spain; Department of Pathology (M.N.), University of Pennsylvania, Philadelphia; Pediatric Neuroimmunology Unit (V.G.-Á., T.A.), Sant Joan de Déu Children's Hospital, University of Barcelona, Spain; Department of Pathology (M.S.), Sant Joan de Déu Children's Hospital, University of Barcelona, Spain; and Neuroimmunology Program (A.S., T.A.), IDIBAPS-Hospital Clinic, University of Barcelona, Spain.

Funding information and disclosures are provided at the end of the article. Full disclosure form information provided by the authors is available with the full text of this article at [Neurology.org/NN](http://Neurology.org/NN).

The Article Processing Charge was funded by the Clinic Foundation.

This is an open access article distributed under the terms of the Creative Commons Attribution-NonCommercial-NoDerivatives License 4.0 (CC BY-NC-ND), which permits downloading and sharing the work provided it is properly cited. The work cannot be changed in any way or used commercially without permission from the journal.

## Glossary

MMF = mycophenolate mofetil; MOG = myelin oligodendrocyte glycoprotein.

The diagnosis of small vessel primary CNS vasculitis is challenging because conventional and brain MRI angiography are negative, and brain biopsy remains as the only definite diagnostic test.<sup>1</sup> However, brain biopsy is invasive and may be uninformative because of sampling error. Here, we describe 2 patients with myelin oligodendrocyte glycoprotein (MOG) antibody-associated encephalitis<sup>2</sup> who were initially misdiagnosed with small vessel CNS vasculitis based on biopsy findings. Physicians should be aware of this potential misdiagnosis because it has important clinical implications.

### Case 1

A 5-year-old boy presented with 2 weeks of frontal headache and fever. His physical examination showed decreased alertness and bilateral papilledema (table). Brain CT and MRI (figure 1A) were normal, and the CSF showed pleocytosis. Meningoencephalitis was suspected, and he was started on steroids and acyclovir. During the following days, he developed visual hallucinations. There was gradual clinical improvement until complete recovery, and the patient was discharged on steroid taper 1 month later. In the ensuing 4 months, he was readmitted 3 times for relapsing symptoms while weaning from steroids. Repeat brain MRI showed T2 abnormalities in the basal ganglia, cerebellar peduncles, and supratentorial white matter (figure 1B–D), and CSF pleocytosis was identified in all episodes (table). All relapses substantially improved after treatment with steroids. At the last relapse, a conventional brain angiography was inconclusive. Brain biopsy showed infiltrates of lymphocytes involving the wall of small vessels and perivascular areas accompanied by perivascular demyelination (figure 2A–D). The patient was diagnosed with primary CNS vasculitis, and he was started on monthly pulses of cyclophosphamide. After the 5th pulse, he developed acute right optic neuritis that was treated with steroids, resulting in little improvement. Extensive blood testing identified an elevation of lipoprotein A (also present in his asymptomatic father), and oral aspirin was added, together with mycophenolate mofetil (MMF) and prednisone. He remained clinically and radiologically stable (figure 1E), with a right eye visual deficit for 2 years; at this time, immunosuppression was weaned, and shortly after stopping the steroids (while on MMF and aspirin), he developed confusion and decreased level of consciousness. MRI showed extensive white matter abnormalities (figure 1F) and high serum titer of MOG antibodies (1:640). Retrospective assessment of stored serum and CSF obtained at onset of the disease were also positive for MOG antibodies (serum titer 1:20,480 and CSF 1:320, table). Review of the paraffin block containing

the brain biopsy showed that the inflammatory infiltrates were not confined to the vessel wall and also involved the white and gray matter. With these findings, the patient was diagnosed with anti-MOG encephalitis, and treatment with rituximab, azathioprine, and low-dose prednisone was initiated. No more relapses were observed; at the last follow-up, 3 years later, he remained clinically and radiologically stable on azathioprine and low-dose prednisone (eventually discontinued), and the serum titer of MOG immunoglobulin G (IgG) antibodies had decreased (1:80) below the consensus limit of positivity ( $\geq 1:160$ ).<sup>2,3</sup>

### Case 2

A 39-year-old woman with a history of ulcerative colitis treated with mesalamine and budesonide developed severe, progressive left temporo-parietal headache associated with nausea and photophobia. Shortly after neurologic symptom onset, she developed intermittent fever. Peripheral leukocytosis with neutrophilic predominance and elevated C-reactive protein were identified (table). Brain MRI showed hyperintense gyriform fluid-attenuated inversion recovery signal over the left temporal, parietal, and occipital lobes (figure 1G–H). CSF analysis showed pleocytosis and elevated protein concentration, and the patient was started on empiric antibiotics and acyclovir. Six days later, she developed expressive aphasia, confusion, and agitation, and bilateral VI cranial nerve palsies. Repeat brain MRI showed no changes, and CT angiography demonstrated no clear evidence of vasculitis. A biopsy of the left parietal lobe and dura showed interstitial and perivascular lymphocytic infiltrates with marked involvement of the vessel wall (figure 2E–H). There was no clear evidence of demyelination (data not shown). These findings led to suspect CNS vasculitis, and high-dose IV steroids and oral cyclophosphamide were started. Four months later, cyclophosphamide was discontinued because of elevated transaminases. The dose of prednisone was tapered over the course of 2 years. During the follow-up, the brain MRI normalized at 4 months and the neurologic examination at 9 months; her only complaints were mild aphasia when tired and chronic daily headache. Retrospective analysis of stored CSF obtained by the time of symptom onset showed MOG-IgG antibodies (1:8).

## Discussion

We describe 2 patients initially diagnosed with small vessel CNS vasculitis but who in fact had anti-MOG-associated encephalitis. The first patient received standard treatment for CNS vasculitis, including cyclophosphamide and steroid-sparing drugs. Although this treatment led to initial stabilization of symptoms, the patient developed new relapses until

**Table** Clinical and laboratory data of 2 patients with anti-MOG encephalitis initially misdiagnosed with small CNS vessel vasculitis

	Patient 1						Patient 2
<b>Age, sex</b>	5 years, male						39 years, female
<b>Previous history</b>	None						Ulcerative colitis
<b>Attack</b>	1	2	3	4	5	6	1
<b>Time from disease onset</b>	Onset	+4 wk	+6 wk	+4 mo	+8 mo	+30 mo	Onset
<b>Symptoms</b>	Headache, LGF, papilledema, bilateral visual loss, confusion, and hallucinations	Headache and LGF	Headache, blurry vision, unsteady gait, and DLC	LGF, right leg paresis, hallucinations, and DLC	Pain, severe loss of vision on the right eye, and papilledema	Confusion and DLC	Headache, nausea, photophobia, fatigue, diarrhea, LGF, aphasia, and irritability. Later: bilateral VI cranial nerve palsy
<b>Systemic inflammatory markers</b>	Normal CRP and ESR	Normal CRP, ESR, and ferritin	Normal CRP and ESR	Normal CRP, ESR, elevation of lipoprotein A, <sup>a</sup> and elevated vWF (150%) <sup>b</sup>	n.d.	Normal CRP, ESR, and vWF	Mildly elevated CRP (3.62 mg/dL) and normal ferritin
<b>CSF studies</b>	1st d; 4th d						1st d; 7th d; 8th d
<b>WBC (cell/mm<sup>3</sup>)</b>	50; 5	40	10	30	n.d.	5	64; 146; 112
<b>Protein (mg/dL)</b>	31; 26	54	50	68	n.d.	29	49; 65; 98
<b>Neopterin (nmol/L) (NR 9–55)</b>	115	528	n.d.	146	n.d.	36	
<b>OCB</b>			Positive	Negative			
<b>Anti-MOG Ab serum titer; CSF titer<sup>c</sup></b>	n.d.; positive (1:320)	Positive (1:20480); n.d.	n.d.; n.d.	n.d.; n.d.	Positive (1:2,560); n.d.	Positive (1:640); n.d.	n.d.; positive (1:8)
<b>Brain MRI</b>	Normal (figure 1A)	Basal ganglia (figure 1B)	Cerebral peduncle (figure 1C)	Asymmetric large hazy white matter and basal ganglia lesions (figure 1D)	No new lesions; residual extensive white matter lesions (figure 1E)	New large hazy white matter lesions (figure 1F)	T2/FLAIR cortical hypersignal, edema, meningeal enhancement. Solitary enhancing T2 hyperintense white matter lesions (figure 1, G–H)
<b>Treatment</b>	Acyclovir, IV dexamethasone, oral steroids, and levomepromazine	Acyclovir, IV methylprednisolone, and oral steroids	IVIg, oral steroids, and nifedipine	IV methylprednisolone, oral steroids, and pulses of CYC	IV methylprednisolone, oral steroids, MM, and aspirin	IV methylprednisolone, AZA, RTX, <sup>d</sup> oral steroids, and aspirin	Vancomycin, ceftriaxone, doxycycline acyclovir, and IVIg. After brain biopsy: IV steroids, CYC, MM, and oral steroids

Continued

**Table** Clinical and laboratory data of 2 patients with anti-MOG encephalitis initially misdiagnosed with small CNS vessel vasculitis (*continued*)

	Patient 1		Patient 2	
<b>Clinical response to immunotherapy</b>	Complete	Complete	Complete; MRI residual lesions	Nearly complete; residual MRI lesions.
<b>Last follow-up</b>	Complete 6 y, left eye visual loss and mild deficit of attention; extensive MRI white matter residual lesions. Serum anti-MOG titers <sup>c</sup> (1:80); current treatment: AZA and low-dose aspirin <sup>d</sup>	Complete	Complete; MRI residual lesions	Nearly complete; normalization of brain MRI  9 mo: mild aphasia when tired and chronic daily headache

Abbreviations: Ab = antibody; AZA = azathioprine; CRP = C-reactive protein; CYC = cyclophosphamide; DLC = decreased level of consciousness; ESR = erythrocyte sedimentation rate; FLAIR = fluid-attenuated inversion recovery; IV = intravenous; IVIg = IV immunoglobulin; LGF = low-grade fever; MM = myelin oligodendrocyte glycoprotein; n.d. = not done; NR = normal range; OCB = oligoclonal band; RTX = rituximab, S = serum; WWF = von Willebrand factor; WBC = white blood cell.

<sup>a</sup> Also present in his asymptomatic father.

<sup>b</sup> NR: 60%–120%.

<sup>c</sup> Threshold for positive results, CSF ( $\geq 1:2$ ), and serum ( $\geq 1:160$ ).<sup>2,3</sup>

<sup>d</sup> Only 1 cycle of RTX was given (4 weekly 375 mg/m<sup>2</sup> doses) due to CD19 counts <2% of lymphocytes since then.

he was transitioned to a B-cell depletion therapy with good clinical and serologic response. In the second patient, the finding of MOG antibodies did not change the treatment strategy because she was already clinically stable; however, an earlier detection of these antibodies could have prevented the brain biopsy.

In retrospect, none of these patients fulfilled the criteria for small vessel CNS vasculitis. Although the presence of inflammatory cells in the vessel walls is sufficient to diagnose medium or large vessel vasculitis, signs of vessel damage such as fibrin deposition and/or necrosis (absent in our patients) must also be present to meet the criteria for small vessel vasculitis. Diapedesis of leukocytes takes place in small vessels, and the presence of inflammatory cells in the walls does not necessarily imply a pathologic process. Moreover, the pathology of CNS vasculitis is usually focal or segmental, and the brain biopsy specimen can be negative or not meet the full diagnostic criteria.<sup>4</sup> As our patients reveal, the presence of lymphoid cells in vessel walls must be interpreted with caution, particularly when the differential diagnosis includes encephalitis with lymphocytic infiltrates. In this context, the presence of lymphocytes in the brain parenchyma away from the vessel walls favors secondary involvement of the vessels rather than a primary vasculitic process. Whether other cases of anti-MOG encephalitis may have been misdiagnosed as CNS vasculitis is unknown. There are reports of patients diagnosed with CNS small vessel vasculitis by brain biopsy who later developed myelitis or optic neuritis<sup>5</sup> (symptoms suggestive of MOG encephalitis),<sup>2,3</sup> making us to postulate that this misdiagnosis may not be unusual.

### Acknowledgment

The authors thank Professor Josep Dalmau for his valuable critical review of the manuscript.

### Study funding

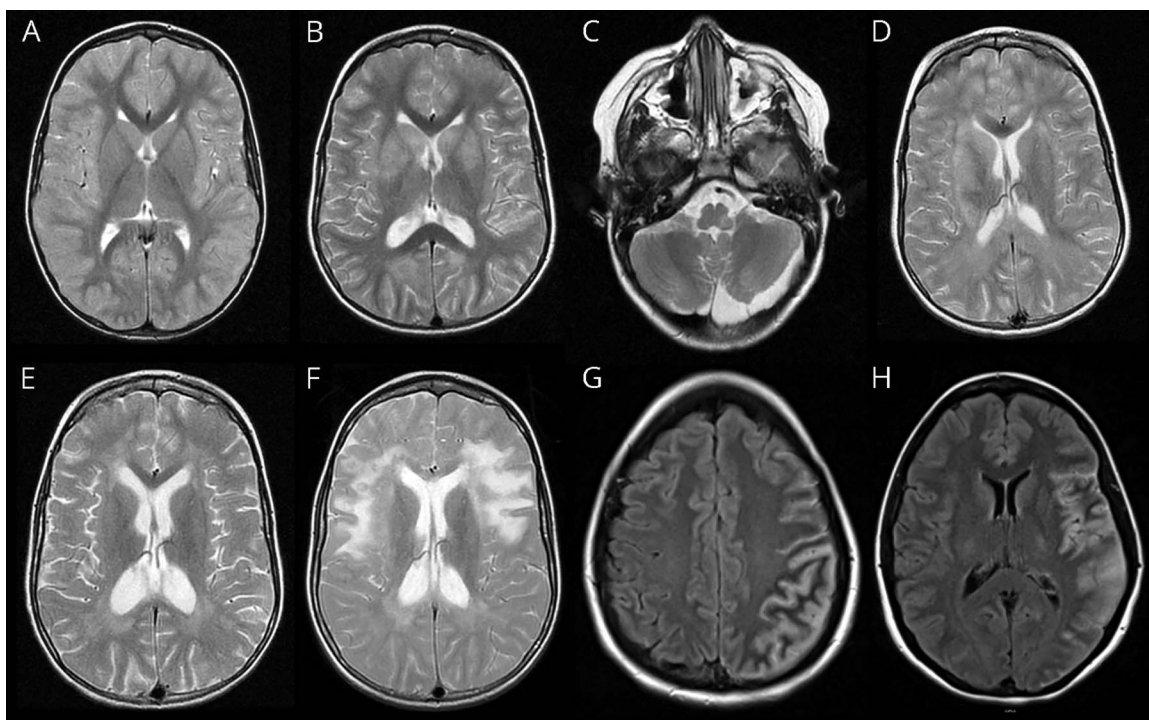
This study was supported in part by Fundació Marató de TV3 (20141830).

### Disclosure

K. Patterson received research support from the NIH/NINDS. E. Iglesias, M. Narallah, V. Gonzalez-Alvarez, and M. Sunol report no disclosures. J. Anton served on the scientific advisory boards of Novartis, Sobi, and Gebro; received travel funding and/or speaker honoraria from AbbVie, Roche, Pfizer, Sobi, and Gebro; and served on the speakers' bureau of AbbVie, Pfizer, Roche, and Gebro. A. Saiz received consulting compensation and speaker honoraria from Bayer-Schering, Merck Serono, Biogen Idec, Sanofi-Aventis, Teva, Novartis, and Roche. E. Lancaster served on the advisory boards of Grifols, Amgen, and Janssen; received speaker honoraria and travel funding from Grifols; consulted for Medimmune, Merck, and Novartis; received fees from the Federal Vaccine Injury Compensation Program; received research support from Grifols and the NINDS; and provided



**Figure 1** MRI of 2 patients with anti-MOG encephalitis initially misdiagnosed with small vessel CNS vasculitis

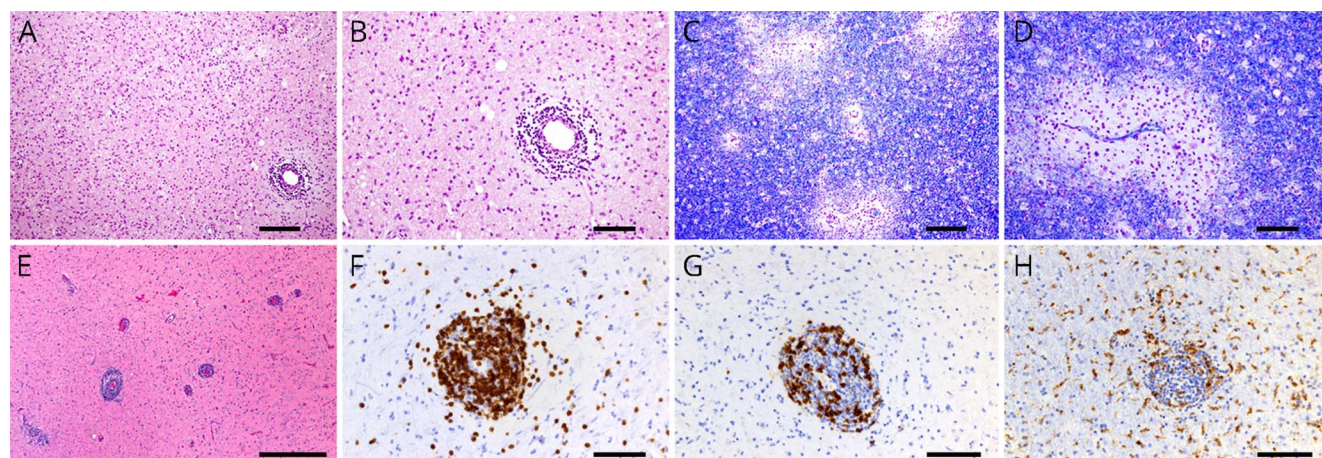


Patient 1: (A) Axial T2 MRI sequence showing no abnormalities at disease onset; (B) bilateral involvement of the basal ganglia 4 weeks after disease onset while steroids were being decreased; (C) left cerebral peduncle abnormality at 6-week follow-up; (D) asymmetric large hazy white matter and basal ganglia lesions at 4 months; (E) residual white matter lesions and enlargement of ventricles due to brain atrophy; and (F) new asymmetric large hazy white matter lesions 30 months after disease onset when steroids were discontinued. Patient 2: (G and H) Axial FLAIR sequences showing gyriform hyperintensities with edema similar to abnormalities previously reported in cases of anti-MOG-associated cortical encephalitis.<sup>6</sup>

medical legal consultation for Rogers Towers PA, Orlando Health, and Wilson, Elser, Moskowitz, Edelman & Dicker LLP. T. Armangue received research support from the Mutua

Madriñena Foundation. Full disclosure form information provided by the authors is available with the full text of this article at [Neurology.org/NN](http://Neurology.org/NN).

**Figure 2** Brain biopsy of 2 patients with anti-MOG encephalitis initially misdiagnosed with small vessel CNS vasculitis



In patient 1, biopsy of the right temporal lobe showed small vessel perivascular lymphocytic infiltration (A, hematoxylin-eosin staining; B, magnification of the vessel shown in panel A). Inflammatory infiltrates included T and B lymphocytes (not shown) in association with edema, perivascular demyelination, and reactive gliosis (C and D, luxol fast blue staining). In patient 2, biopsy of the left temporal lobe showed marked perivascular lymphocytic infiltrates involving the vessel wall (E, hematoxylin-eosin staining). The infiltrates were also composed of T lymphocytes (F, CD3 immunostaining), B lymphocytes (G, CD20 immunostaining), and macrophages (H, anti-CD68 immunostaining). Myelin staining did not show clear evidence of demyelination (not shown). No necrosis or fibrin deposition was identified (not shown). Scale bar 200  $\mu$ m in A and C, 500  $\mu$ m in E, and 100  $\mu$ m in B, D, and F-H.

## Publication history

Received by *Neurology: Neuroimmunology & Neuroinflammation* August 16, 2018. Accepted in final form October 19, 2018.

### Appendix 1 Author contributions

Name	Location	Role	Contribution
<b>Kristina Patterson, MD, PhD</b>	University of Pennsylvania, Philadelphia	Author	Analyzed the data and drafted the manuscript
<b>Estibaliz Iglesias, MD, PhD</b>	University of Barcelona, Barcelona	Author	Analyzed the data and critically reviewed the manuscript
<b>Maclean Nasrallah, MD, PhD</b>	University of Pennsylvania, Philadelphia	Author	Analyzed the data, critically reviewed the manuscript, and developed figure 2
<b>Verónica González-Alvarez, MD</b>	University of Barcelona, Barcelona	Author	Analyzed the data and critically reviewed the manuscript
<b>Mariona Suñol, MD</b>	University of Barcelona, Barcelona	Author	Analyzed the data, critically reviewed the manuscript, and developed figure 2
<b>Jordi Anton, MD, PhD</b>	University of Barcelona, Barcelona	Author	Analyzed the data and critically reviewed the manuscript
<b>Albert Saiz, MD, PhD</b>	University of Barcelona, Barcelona	Author	Analyzed the data and critically reviewed the manuscript
<b>Eric Lancaster, MD, PhD</b>	University of Pennsylvania, Philadelphia	Author	Analyzed the data and critically reviewed the manuscript
<b>Thaís Armangue, MD, PhD</b>	University of Barcelona, Barcelona	Author	Designed and conceptualized the study; analyzed the data; drafted the manuscript; and developed the figures

## References

1. Benseler SM, deVeber G, Hawkins C, et al. Angiography-negative primary central nervous system vasculitis in children: a newly recognized inflammatory central nervous system disease. *Arthritis Rheum* 2005;52:2159–2167.
2. Jarius S, Paul F, Aktas O, et al. MOG encephalomyelitis: international recommendations on diagnosis and antibody testing. *J Neuroinflammation* 2018;15:134.
3. Höftberger R, Sepulveda M, Armangue T, et al. Antibodies to MOG and AQP4 in adults with neuromyelitis optica and suspected limited forms of the disease. *Mult Scler* 2015;21:866–874.
4. Giannini C, Salvarani C, Hunder G, Brown RD. Primary central nervous system vasculitis: pathology and mechanisms. *Acta Neuropathol* 2012;123:759–772.
5. Benseler S, Pohl D. Childhood central nervous system vasculitis. *Handb Clin Neurol* 2013;112:1065–1078.
6. Ogawa R, Nakashima I, Takahashi T, et al. MOG antibody-positive, benign, unilateral, cerebral cortical encephalitis with epilepsy. *Neurol Neuroimmunol Neuroinflamm* 2017;4:e322. doi: 10.1212/NXI.0000000000000322.

# Neurology<sup>®</sup> Neuroimmunology & Neuroinflammation

## Anti-MOG encephalitis mimicking small vessel CNS vasculitis

Kristina Patterson, Estibaliz Iglesias, Maclean Nasrallah, et al.

*Neurol Neuroimmunol Neuroinflamm* 2019;6;

DOI 10.1212/NXI.0000000000000538

This information is current as of February 1, 2019

<b>Updated Information &amp; Services</b>	including high resolution figures, can be found at: <a href="http://nn.neurology.org/content/6/2/e538.full.html">http://nn.neurology.org/content/6/2/e538.full.html</a>
<b>References</b>	This article cites 6 articles, 1 of which you can access for free at: <a href="http://nn.neurology.org/content/6/2/e538.full.html##ref-list-1">http://nn.neurology.org/content/6/2/e538.full.html##ref-list-1</a>
<b>Citations</b>	This article has been cited by 1 HighWire-hosted articles: <a href="http://nn.neurology.org/content/6/2/e538.full.html##otherarticles">http://nn.neurology.org/content/6/2/e538.full.html##otherarticles</a>
<b>Subspecialty Collections</b>	This article, along with others on similar topics, appears in the following collection(s): <b>All Demyelinating disease (CNS)</b> <a href="http://nn.neurology.org/cgi/collection/all_demyelinating_disease_cns">http://nn.neurology.org/cgi/collection/all_demyelinating_disease_cns</a> <b>Autoimmune diseases</b> <a href="http://nn.neurology.org/cgi/collection/autoimmune_diseases">http://nn.neurology.org/cgi/collection/autoimmune_diseases</a> <b>Vasculitis</b> <a href="http://nn.neurology.org/cgi/collection/vasculitis">http://nn.neurology.org/cgi/collection/vasculitis</a>
<b>Permissions &amp; Licensing</b>	Information about reproducing this article in parts (figures,tables) or in its entirety can be found online at: <a href="http://nn.neurology.org/misc/about.xhtml#permissions">http://nn.neurology.org/misc/about.xhtml#permissions</a>
<b>Reprints</b>	Information about ordering reprints can be found online: <a href="http://nn.neurology.org/misc/addir.xhtml#reprintsus">http://nn.neurology.org/misc/addir.xhtml#reprintsus</a>

*Neurol Neuroimmunol Neuroinflamm* is an official journal of the American Academy of Neurology. Published since April 2014, it is an open-access, online-only, continuous publication journal. Copyright Copyright © 2019 The Author(s). Published by Wolters Kluwer Health, Inc. on behalf of the American Academy of Neurology.. All rights reserved. Online ISSN: 2332-7812.

