

Cranial nerve involvement in patients with MOG antibody–associated disease

Alvaro Cobo-Calvo, MD, PhD, Xavier Ayrygnac, MD, PhD, Philippe Kerschen, MD, Philippe Horellou, PhD, Francois Cotton, MD, PhD, Pierre Labauge, MD, PhD, Sandra Vukusic, MD, PhD, Kumaran Deiva, MD, PhD, Chè Serguera, MD, PhD,* and Romain Marignier, MD, PhD*

Correspondence
Dr. Marignier
romain.marignier@chu-lyon.fr

Neurol Neuroimmunol Neuroinflamm 2019;6:e543. doi:10.1212/NXI.0000000000000543

Abstract

Objective

To describe clinical and radiologic features of cranial nerve (CN) involvement in patients with myelin oligodendrocyte glycoprotein antibodies (MOG-IgG) and to assess the potential underlying mechanism of CN involvement using a nonhuman primate (NHP) model.

Methods

Epidemiologic, clinical, and radiologic features from a national cohort of 273 MOG-IgG–positive patients were retrospectively reviewed for CN involvement between January 2014 and January 2018. MOG-IgG binding was evaluated in CNS, CN, and peripheral nerve tissues from NHP.

Results

We identified 3 MOG-IgG–positive patients with radiologic and/or clinical CN involvement. Two patients displayed either trigeminal or vestibulocochlear nerve lesions at the root level, and the remaining patient had an oculomotor nerve involvement at the root exit and at the cisternal level. Additional CNS involvement was found in all 3 patients. None of the 3 patients' sera recognized MOG expression in CN of NHP.

Conclusion

Cranial nerve involvement can coexist in patients with MOG antibody disease, although the underlying pathophysiology remains elusive.

*These authors contributed equally to the manuscript.

From the Service de neurologie (A.C.-C., S.V., R.M.), sclérose en plaques, pathologies de la myéline et neuroinflammation and Centre de référence pour les maladies inflammatoires rares du cerveau et de la moelle (MIRCEM)– Hôpital Neurologique Pierre Wertheimer Hospices Civils de Lyon, France; Lyon Neuroscience Research Center (A.C.-C., R.M.), U1028 INSERM, UMR5292 CNRS, FLUID Team, Lyon, France; Service de sclérose en plaques (X.A., P.L.), Hôpital Universitaire de Montpellier, France; Service de Neurologie (P.K.), Centre hospitalier de Luxembourg; Inserm (P.H.), U 1184, Center for Immunology of Viral Infections and Autoimmune Diseases, Université Paris-Sud 11, CEA, DSV/iMETI, Division of Immunovirology, IDMIT, Faculté de médecine, Le Kremlin-Bicêtre Cedex, France; Service de Radiologie (F.C.), Centre Hospitalier Lyon-Sud, Hospices Civils de Lyon, Pierre-Bénite, France; Université Claude Bernard Lyon 1 (F.C., S.V., R.M.), F-69100 Villeurbanne, France; Lyon's Neuroscience Research Center (S.V.), Observatoire Français de la Sclérose en Plaques, INSERM 1028 et CNRS UMR5292, Lyon, France; Service de neurologie pédiatrique (K.D.), Centre de référence pour les maladies inflammatoires rares du cerveau et de la moelle, Le Kremlin-Bicêtre, France; and INSERM US27 MIRCEM (C.S.), CEA, Fontenay-aux-Roses, France.

Funding information and disclosures are provided at the end of the article. Full disclosure form information provided by the authors is available with the full text of this article at Neurology.org/NN.

The Article Processing Charge was funded by the authors.

This is an open access article distributed under the terms of the Creative Commons Attribution-NonCommercial-NoDerivatives License 4.0 (CC BY-NC-ND), which permits downloading and sharing the work provided it is properly cited. The work cannot be changed in any way or used commercially without permission from the journal.

Glossary

AQP4 = aquaporin-4; **CN** = cranial nerve; **hMOG** = human MOG; **MBP** = myelin basic protein; **MFI** = mean fluorescence intensity; **MOG** = myelin oligodendrocyte glycoprotein; **MTP** = methylprednisolone; **NHP** = nonhuman primate; **NMOSD** = neuromyelitis optica spectrum disorder; **OCB** = oligoclonal band; **OFSEP** = Observatoire Français de la Sclérose en Plaques; **RT** = room temperature.

Antibodies against myelin oligodendrocyte glycoprotein (MOG-IgG) are a well-recognized cause of demyelination in adults and children with acute disseminated encephalomyelitis^{1,2} and neuromyelitis optica spectrum disorders (NMOSDs).^{3–6} New clinical phenotypes such as cortical encephalitis, brainstem syndromes,^{7–10} and fulminant cases^{10,11} have been more recently reported, suggesting that the clinical and radiologic presentation of MOG antibody-associated disease could be broader than previously thought. Cranial nerve (CN) involvement in patients with serum MOG-IgG has not been described so far.

We report here clinical and radiologic features of 3 MOG-IgG-positive patients with CN involvement. To evaluate the possible underlying mechanism of MOG-IgG in the present clinical phenotype, we screened patients' sera for reactivity in the CNS, CN, and peripheral nerve from nonhuman primate (NHP) (cynomolgus macaque).

Methods

Patients

Epidemiologic, clinical, and radiologic data were retrospectively reviewed from the adult (n = 197)¹⁰ and pediatric (n = 76) French cohorts of MOG-IgG-positive patients diagnosed between January 2014 and January 2018.

MRI was performed in the clinical setting including axial and sagittal images of the brain and spinal cord obtained by T1-, T2-, fluid attenuated inversion (FLAIR), and T1-weighted postcontrast sequences.

For experiments, sera from MOG-IgG-positive patients with CN involvement and controls were used. As controls, we selected 1 MOG-IgG-positive patient with an exclusive CNS involvement, 1 healthy control, and 1 double-seronegative (MOG and aquaporin-4 [AQP4]-IgG-negative) NMOSD patient.

Standard protocol approvals, registrations, and patient consents

The study was approved by the Ethics Committee of the University Hospital of Lyon, France. All patients provided their informed consent to participate in the study.

This study was conducted within the framework of Observatoire Français de la Sclérose en Plaques (OFSEP). Because of national confidentiality requirements, only anonymized data, not pseudonymized data, can be shared. Although

anonymization techniques might result in impoverishment of data (Article 29 of Directive 95/46/EC, Opinion 05/2014 on Anonymization Techniques—0829/14/EN WP 216), data used for this study were only pseudonymized. However, access to OFSEP data to conduct a scientific project is possible by following the OFSEP data access process (ofsep.org/en/data-access) and with respect to French law.

Autoantibody detection

All samples were examined for IgG against human MOG (hMOG) and human AQP4 by cell-based assays.^{12,13} Briefly, for MOG antibodies, HEK293 cells were transfected with pEGFP-N1-hMOG plasmid (kindly provided by Markus Reindl, Innsbruck, Austria). After 48 hours, transfected cells were dissociated with Accutase (Sigma-Aldrich, A6964) and incubated with phosphate-buffered saline (PBS) 8% normal goat serum (NGS) for 30 minutes at room temperature (RT). Then, patients' sera diluted at 1:640 were incubated with transfected cells for 30 minutes at 4°C. This cutoff was selected to avoid false-positive signal detected with healthy controls in previous studies.¹⁴ Cells were fixed with 1% paraformaldehyde (PFA) for 15 minutes and then incubated 20 minutes at RT in the dark with a secondary antibody allophycocyanin (APC)-goat anti-human IgG-Fcγ fragment-specific (1:100 dilution, Jackson ImmunoResearch 109-136-170).

For the detection of AQP4 autoantibody, HEK293 cells were transfected with pcDNA3.1-AQP4-M23 and pEGF-C1 plasmids with Lipofectamine LTX (Invitrogen 10573013). After 48 hours, cells were dissociated with Accutase (Sigma-Aldrich, A6964) and incubated with PBS 8% NGS for 30 minutes. After blocking, cells were incubated with patients' sera at 1:100 cells for 30 minutes at 4°C and then fixed with 1% PFA at RT for 15 minutes. HEK293 cells were incubated for 20 minutes at RT in the dark with a secondary antibody APC-goat anti-human IgG-Fcγ fragment-specific (1:100 dilution, Jackson ImmunoResearch 109-136-170). FACS analysis for MOG and AQP4-IgG was performed with the CANTO II flow cytometer (Becton Dickinson).

In addition, serum samples were tested for antibodies against neuronal cell surface antigens using rat brain immunohistochemistry, as described previously.¹⁵

Nonhuman primate tissue preparation and immunohistochemistry

Nonhuman primates

Adult captive-bred 3- to 5-year-old female cynomolgus macaques (*Macaca fascicularis*) were used.^{16,17} Brains were

sampled after intracardiac perfusion with PBS and 4% PFA. Brains were postfixed by overnight immersion in 4% PFA and then transferred to PBS and embedded in paraffin. For immunohistochemistry analysis, 3- to 5- μ m-thick paraffin sections from brain, cerebellum, oculomotor, trigeminal, and sciatic nerves were cut and deparaffinized.

Immunohistochemistry

To assess myelin staining pattern in NHP tissues, IgGs were purified as previously described.¹⁸ Purified IgG from each patient were labeled with Alexa Fluor 594 (referred to as purified IgG-AF594) Microscale Protein Labeling Kit (Invitrogen; 30008), according to the manufacturer's instruction to prevent background signal associated with the use of secondary anti-human IgG antibodies in macaque brain tissues (nonpublished observations). To ascertain that the purified IgG-AF594 from MOG-positive patients still bound to MOG antigen, we performed flow cytometry cell-based assay and compared Δ -mean fluorescence intensity (MFI), determined by the subtraction of MFI obtained with HEK293 control cells from that obtained with HEK293 MOG-positive cells. The levels measured for the 3 patients with CN involvement were at the same level as the one obtained with the positive control patient or above (figure e-1, links.lww.com/NXI/A97).

Purified IgG-AF594 from MOG-IgG-positive patients and controls were incubated with macaque tissue slices (diluted 1:20) for 1 hour and 30 minutes following 30 minutes of saturation with a block solution (BSA5%, 10% NGS). Myelin was also labeled with a commercial mouse monoclonal MOG antibody (clone 8-18C5, MAB5680; Millipore) as a positive control, and a biotinylated goat anti-mouse antibody (1:200, BA9200, Vector Laboratories, Burlingame, CA) was used as secondary, for 30 minutes at RT, followed by the avidin-biotin-peroxidase complex (Vectastain Elite ABC Kit, PK 6100, Vector Laboratories, Burlingame, CA). Positive antigen-antibody reactions were visualized by incubation with 3,3'-diaminobenzidine tetrahydrochloride H_2O_2 in 0.1 M imidazole, pH 7.1 for 5 minutes, followed by slight counterstaining with hematoxylin. A mouse monoclonal anti-myelin basic protein (MBP) was used to confirm myelin staining (dilution 1/200) (LS B2231, LifeSpan Bioscience), followed by a secondary goat anti-mouse antibody coupled to fluorochromes Alexa 488 (dilution 1/500) (A32731, Thermo Fisher Scientific). Labeled tissues were analyzed and pictured with confocal microscopy.

Results

Patient clinical and radiologic characteristics

We identified 3 (2 adult and 1 pediatric) MOG-IgG-positive patients with clinical or radiologic CN involvement.

Patient Id.1

A 76-year-old man with a medical history of hypertension and dyslipidemia developed insidiously general fatigue, and 1 month later a left facial numbness. Neurologic examination revealed left facial hypesthesia (ophthalmic, maxillary, and mandibular

divisions) and dysmetria of the left arm. Brain MRI revealed FLAIR hyperintensities of both upper cerebellar peduncles with gadolinium enhancement (figure 1A). Left trigeminal nerve showed a gadolinium enhancement at the root level (figure 1B). CSF revealed 0.52 g/L of proteins without cells or oligoclonal bands (OCBs). A whole-body 18-fluorodeoxyglucose PET/CT imaging showed no abnormalities. Symptoms improved spontaneously without treatment, and the patient did not receive any immunoactive drug. Six months later, a new right trigeminal nerve gadolinium enhancement was observed on a routine brain MRI without any new clinical involvement (figure 1C). Two years after onset, the patient remained asymptomatic and the brain MRI showed complete resolution of lesions (figure 1D).

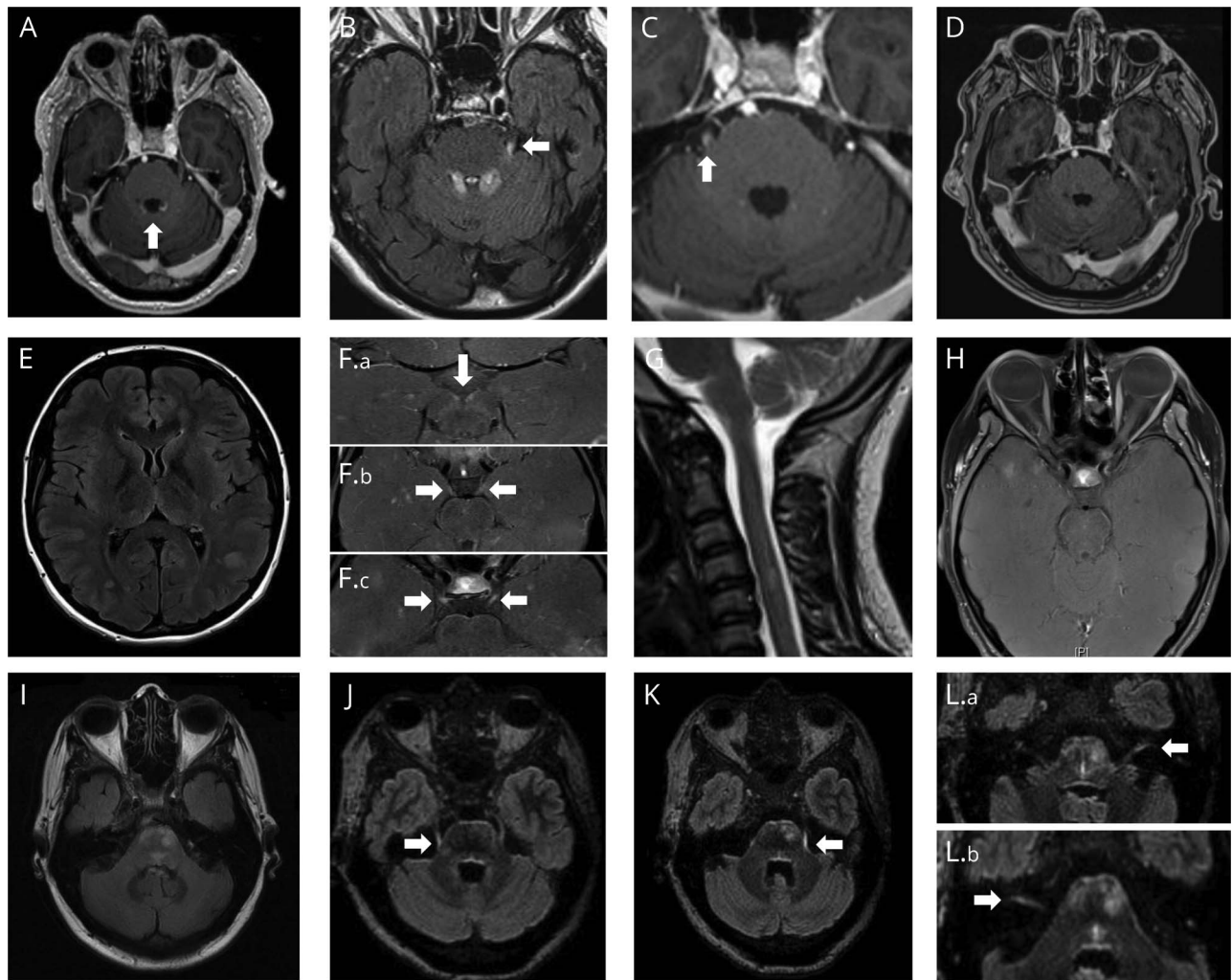
Patient Id.2

A 16-year-old girl with a medical history of idiopathic congenital nystagmus presented with a 5-day history of fever, general mental alteration, and disorientation rapidly associated with dizziness and vomiting, suspected from infectious meningitis. Neurologic examination only found an already known nystagmus in all directions of gaze without other oculomotor disturbances. Lumbar puncture was performed, and she was immediately started on IV amoxicillin and acyclovir. CSF showed neither cells nor OCBs, and proteins and glucose were within the normal range. All viral PCR and bacterial cultures were negative, and IV treatment was stopped. Brain MRI revealed bilateral juxtacortical and supratentorial white matter hyperintensities on FLAIR (figure 1E). Gadolinium enhancement was observed on both third oculomotor nerves at the root exit and at the cisternal level (figure 1F). Spinal MRI revealed a T2 cervical hyperintensity with a subtle gadolinium enhancement (figure 1G). Three months later, a brain MRI scan showed an absence of gadolinium enhancement on the third nerve and partial resolution of the brain FLAIR hyperintensities with no gadolinium enhancement (figure 1H). Four months later, she presented with a decrease in visual acuity on the right eye together with retro-orbital pain. Three days of IV methylprednisolone (MTP) (1 g/d) was started with complete recovery. After 24 months of follow-up, the patient was asymptomatic.

Patient Id.3

A 52-year-old woman with hypertension, hypothyroidism, and chronic kidney disease was admitted for an 8-day history of diplopia, vertigo, and gait instability. Neurologic examination revealed a "one and a half syndrome", a positive Romberg sign, and dizziness. Blood test confirmed a renal insufficiency (creatinine 1.28 mg/dL and glomerular filtration rate 43 mL/min). CSF showed 27 leukocytes (65% lymphocytes), 0.51 g/L of proteins, normal glucose, and no OCBs. Brain MRI showed asymmetrical FLAIR hyperintensities at the medulla oblongata and pons and in the dorsal pontine tegmentum (figure 1I). A bilateral trigeminal and vestibulocochlear nerve gadolinium enhancement was found at the root level (figure 1, J-L). Spinal cord MRI showed no abnormalities. PET/CT imaging showed no hypermetabolic foci. The patient received 5 days of IV MTP (1 g/d) with subsequent clinical recovery. After a follow-up of 12 months, the patient remained asymptomatic with no further treatment.

Figure 1 Radiologic features of human myelin oligodendrocyte glycoprotein immunoglobulin G-positive patients with cranial nerve involvement



Patient Id.1 (A–D). (A) Bilateral upper cerebellar peduncle. (B and C) Left and right trigeminal nerve gadolinium enhancement on T1W postcontrast sequence. (D) Complete resolution of the lesions on T1 postgadolinium. Patient Id. 2 (E–H). (E) White matter cerebral lesions on FLAIR sequences. (F, a–c), Bilateral oculomotor nerve gadolinium enhancement in the cisternal part of the nerve on T1W postcontrast sequence with fat saturation. (G) Focal cervical T2 lesion on spinal cord MRI. (H) Resolution of oculomotor gadolinium enhancement on T1W postcontrast sequence with fat saturation. Patient Id.3 (I–L). (I) Brainstem asymmetric FLAIR hyperintensities and dorsal pontine tegmentum hyperintensity. (J and K) Bilateral trigeminal nerve gadolinium enhancement on FLAIR postcontrast sequence. (L, a and b), Bilateral vestibulocochlear nerve gadolinium enhancement on FLAIR postgadolinium sequence.

MOG-IgG were found positive in serum samples taken at 12 months after first symptoms in patient Id.1 and at onset in patients Id.2 and Id.3. None of the patients had AQP4-IgG or additional antibodies against neuronal cell surface antigens.

Tissue immunohistochemistry

First, we analyzed by immunohistochemistry whether purified IgG-AF594 from the 3 patients with CN involvement reacted with NHP brain slices. Purified IgG-AF594 from all 3 patients allowed myelin staining on brain slices from NHP (table, figure 2A), with similar aspect as that obtained with commercial mouse monoclonal 8-18C5 anti-MOG (figure 2B). In addition, purified IgG-AF594 colocalized with the commercial MBP antibody (figure 2C).

Then, we evaluated whether purified IgG-AF594 of the 3 patients labeled NHP CN or peripheral nerves. None of the purified IgG-AF594 showed positive staining neither in proximal and distal regions of oculomotor, trigeminal, nor in distal regions of the sciatic nerve (figure 3). Equally, neither the purified IgG-AF594 from the MOG-IgG-positive patient with exclusive affection of CNS nor that of the healthy subject or the double-seronegative NMOSD control displayed any staining on trigeminal or sciatic nerves (not shown).

Discussion

In this study, we report clinical and/or radiologic involvement of CNs in MOG-IgG-positive patients, thus enlarging the clinical spectrum of MOG antibody-associated disease.

Table Epitope recognition by human MOG among species in cell-based assays and immunohistochemistry

Patient identification	Cell-based assays	NHP immunohistochemistry	
	Human MOG (1:640)	Brain	Cranial nerves
Id.1	Pos	MSP++	Neg
Id.2	Pos	MSP++	Neg
Id.3	Pos	MSP++	Neg
Control; MOG-IgG positive ^a	Pos	MSP++	Neg
Control; healthy subject	Neg	Neg	Neg
Control; double-seronegative NMOSD	Neg	Neg	Neg

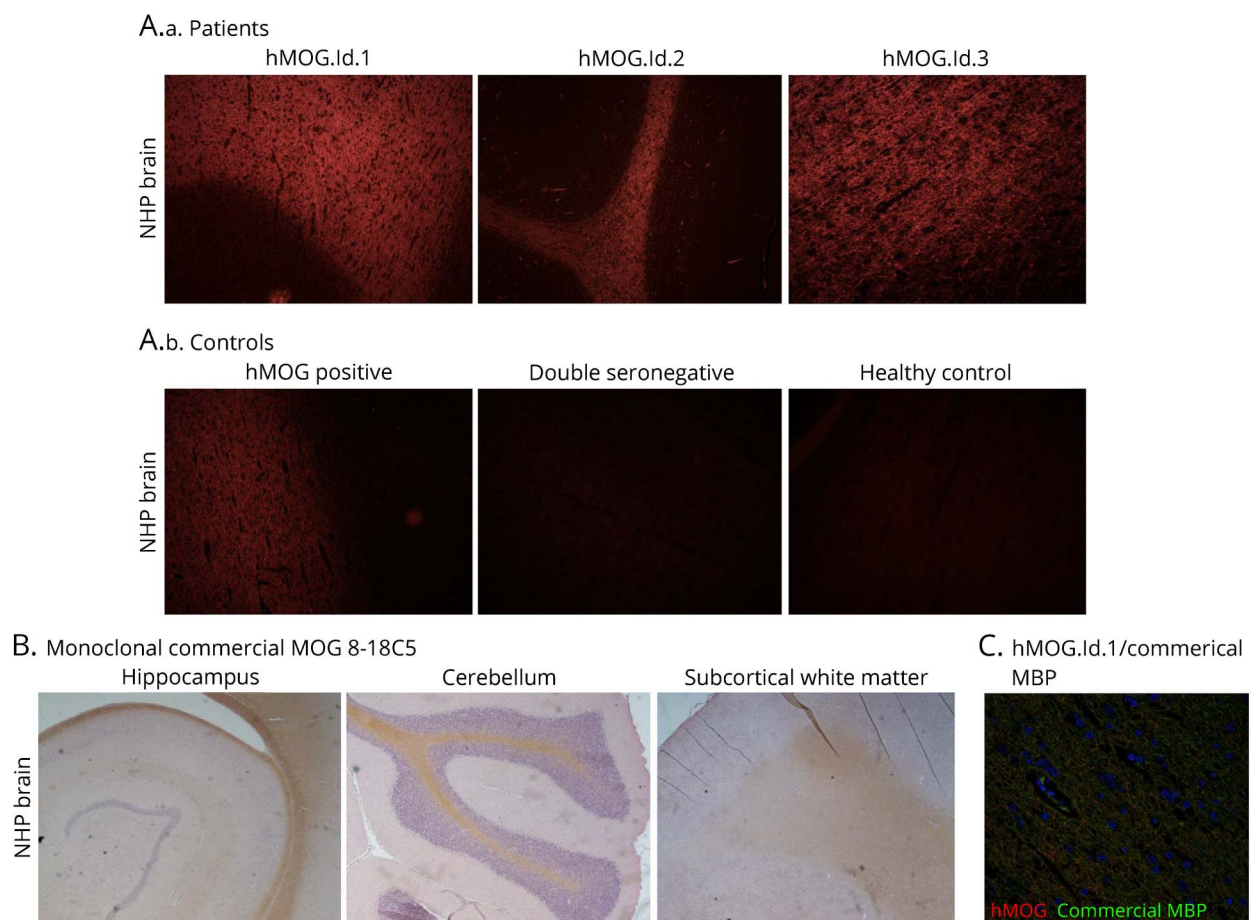
Abbreviations: MOG = myelin oligodendrocyte glycoprotein; MSP = myelin staining pattern; Neg = negative; NHP = nonhuman primate; NMOSD = neuro-myelitis optica spectrum disorder; Pos = positive.

Myelin staining pattern (MSP) was classified as Neg (no staining), + (when slightly), ++ (moderate), and +++ (intense pattern).

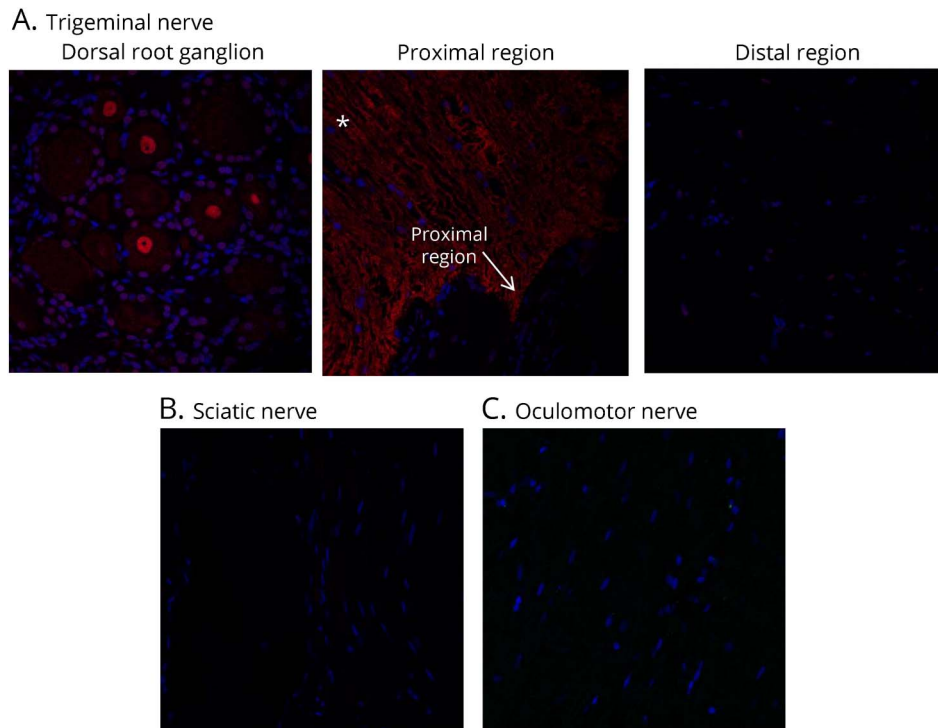
^a The MOG-IgG-positive patient had exclusive involvement of the CNS.

MOG antibody-associated disease is a relatively new entity with a predisposition for the optic nerve and the spinal cord, with encephalic or brainstem structures being less frequently involved.³⁻¹⁰ Among our national cohort of adult and pediatric MOG-IgG-positive patients, 3 of 273 patients (1.1%) had clinical or radiologic involvement of CNs, in addition to CNS involvement.

Figure 2 Nonhuman primate brain immunohistochemistry



(A) Purified IgG-AF594 from patients (A.a) and from controls (A.b). (B) Brain and cerebellum nonhuman primate myelin staining with commercial monoclonal MOG 8-18C5. (C) Purified IgG-AF594 from patients colocalized with commercial anti-MBP. An example of patient Id.1. hMOG = human MOG; MBP = myelin basic protein; MOG = myelin oligodendrocyte glycoprotein; NHP = nonhuman primate.



The 3 patients presented in this study had clinical symptoms or radiologic images related to the involvement of oculomotor, trigeminal, or vestibulocochlear nerves. Two patients displayed gadolinium enhancement of CNs at the transitional zone at the root level. Such region contains an overlap of central and peripheral myelin features whose extension differs among CNs, over 7 and 9 mm in length in trigeminal and vestibulocochlear nerves, respectively.^{19,20} On the contrary, the oculomotor nerve gadolinium enhancement in the third patient extended beyond the anticipated transitional zone between peripheral and central myelin.²¹

To study the underlying pathophysiology of the CN involvement, we used NHP tissues to evaluate MOG-IgG binding in CNS, CN, and peripheral nerve structures. We found that purified immunoglobulins from MOG-IgG-positive patients did not allow labeling neither in proximal nor in distal portions of CNs explored. Because MOG is a protein expressed by oligodendrocytes in the CNS,²² the absence of MOG-IgG binding at the peripheral level in our NHP model was not unexpected. However, the absence of MOG recognition at the transitional zone by the serum of MOG-IgG patients did not permit to confirm a possible role of MOG-IgG over this region. Such CN involvement could also be explained as the result of downstream inflammatory process from the intra-axial pontine lesion. We also may consider that the presence of other specific autoantibodies different from MOG-IgG or an unknown demyelinating process specifically targeting the peripheral nerve could be the cause of CN lesion

rather than a restricted involvement of the transitional zone or a peripheral nerve involvement in continuation to a demyelinating process from the CNS.

We found that all patients showed a similar myelin staining pattern in the brain and cerebellar slices of NHP. Recent studies have shown that only a proportion of IgG from MOG-IgG-positive patients could recognize epitopes shared by humans and rodents.^{7,23} Differences in MOG recognition among species is likely the consequence of a decreased homology in amino acid sequences of MOG with 19 different amino acids of 218 between the mouse and human,^{23,24} but only 5 between macaques and humans. The most frequent recognized MOG epitope by hMOG-IgG resides at position 42 in the CC' loop.²⁵ The disparity on the type of amino acid at this position between human and rodents (proline in humans and serine in rodents) is largely responsible for the lack of epitope recognition between both species.^{24,25} However, this amino acid discrepancy does not exist in the MOG protein sequence between cynomolgus macaques and human who are phylogenetically closer.²⁶ Thus, macaques are a suitable model to test autoantibodies from human autoimmune diseases and could be potentially useful when studying diseases such as MOG antibody-associated disease where the difference in the structure of the protein may lead to an absence of recognition by antibodies.¹⁷

Such inflammation of the peripheral nervous system has been reported in AQP4 antibody-positive NMOSDs. Different

patterns of involvement have been described such as polyneuropathy,^{27,28} radiculopathy,²⁹ myeloradiculitis,³⁰ and second motor neuron involvement.^{31,32} Recently, vestibulo-cochlear nerve lesion as a part of CN involvement has been reported for the first time in NMOSDs.³³ Moreover and similarly to our cases, involvement of the transitional region at the spinal root has also been described in a patient presenting with meningo-radicitis.³⁰ In this case, histopathology showed a loss of AQP4 expression and demyelination, suggesting that the underlying pathophysiology could be explained by the presence of AQP4 protein location at the root level, thus being a target for AQP4-IgG. In MS, radiologic trigeminal nerve involvement has been described up to 2.9% of patients,^{34,35} being not always associated with clinical symptoms, as observed in our patients.³⁵ In some cases, the lesion was also found in the cisternal region, distally from the trigeminal root entry zone.^{35,36} Recently, cisternal oculomotor nerve enhancement has been described in closely relation to the CNS demyelinating lesion.³⁷ In all reported patients with the cisternal oculomotor or trigeminal nerve enhancement,³⁵⁻³⁷ an ancient or recent brainstem lesion was found, which suggests an extension from the CNS inflammation rather than a specific demyelination of the peripheral myelin. Some authors have pointed out that the active

inflammation may persist longer in the peripheral nerve than in the CNS.³⁵

Overall, our findings suggest that CN involvement can coexist in patients with MOG-antibody disease. However, the underlying pathophysiology remains to be elucidated.

Acknowledgment

The authors thank Dr. Albert Saiz (Center of Neuroimmunology, Hospital Clinic, Barcelona, Spain) for having performed different antibody testing and immunohistochemistry experiments. They also thank the group of NeuroBioTec from Hospices Civils de Lyon for supporting this study.

Study funding

This study was supported by a grant from the ARSEP Foundation and a grant provided by the French State and handled by the “Agence Nationale de la Recherche”, within the framework of the “Investments for the Future” program, under the reference ANR-10-COHO-002 Observatoire Français de la Sclérose en Plaques (OFSEP), by the Eugene Devic Foundation against Multiple Sclerosis (EDMUS Foundation), and the patient association “Déchaine Ton Coeur”.

Appendix 1 Author contributions

Author	Location	Role	Contributions
Alvaro Cobo-Calvo, MD, PhD	Hôpital Neurologique Pierre Wertheimer, Hospices Civils de Lyon, Lyon	Author	Study concept and design, performed experiments, acquisition of data, analysis and interpretation, and writing of the manuscript
Xavier Aygnac, MD, PhD	Multiple Sclerosis Clinic, Montpellier University Hospital, Montpellier	Author	Acquisition of data and critical revision of the manuscript for important intellectual content
Philippe Kerschen, MD	Service de Neurologie, Centre Hospitalier de Luxembourg, Luxembourg	Author	Acquisition of data and critical revision of the manuscript for important intellectual content
Philippe Horellou, PhD	Center for Immunology of Viral Infections and Autoimmune Diseases, Division of Immuno-Virology, Le Kremlin-Bicêtre Cedex, France	Author	Performed experiments and critical revision of the manuscript for important intellectual content
Francois Cotton, MD, PhD	Centre Hospitalier Lyon-Sud, Hospices Civils de Lyon, Pierre-Bénite, France	Author	Critical revision of the manuscript for important intellectual content
Pierre Labauge, MD, PhD	Multiple Sclerosis Clinic, Montpellier University Hospital, Montpellier	Author	Acquisition of data and critical revision of the manuscript for important intellectual content
Sandra Vukusic, MD, PhD	Hôpital Neurologique Pierre Wertheimer Hospices Civils de Lyon, Lyon	Author	Critical revision of the manuscript for important intellectual content
Kumaran Deiva, MD, PhD	Service de Neurologie Pédiatrique, Le Kremlin-Bicêtre, France	Author	Acquisition of data and critical revision of the manuscript for important intellectual content
Ché Serguera, MD, PhD	INSERM US27 MIRCen, CEA, Fontenay-aux-Roses, France	Author	Study concept and design, performed experiments, acquisition of data, analysis and interpretation, and writing of the manuscript
Romain Marignier, MD, PhD	Hôpital Neurologique Pierre Wertheimer, Hospices Civils de Lyon, Lyon	Author	Study concept and design, performed experiments, acquisition of data, analysis and interpretation, and writing of the manuscript

Disclosure

A. Cobo-Calvo, X. Avignac, P. Kerschen, P. Horellou, F. Cotton, and P. Labauge report no disclosures. S. Vukusic served on the scientific advisory boards of and consulted for Biogen, Celgene, GeNeuro, Genzyme, MedDay, Merck Serono, Novartis, Roche, Sanofi-Aventis, and Teva; received travel funding and/or speaker honoraria from Biogen, Genzyme, Merck Serono, Novartis, Roche, Sanofi-Aventis, and Teva; and received research support from Biogen, Genzyme, MedDay, Merck Serono, Novartis, Roche, Sanofi-Aventis, and Teva. K. Deiva received travel funding from Biogen, Merck Serono, Genzyme, and Novartis. C. Serguera reports no disclosures. R. Marignier served on the scientific advisory board of MedImmune and received travel funding and speaker honoraria from Biogen, Genzyme, Novartis, Merck Serono, Roche, Sanofi-Aventis, and Teva. Full disclosure form information provided by the authors is available with the full text of this article at Neurology.org/NN.

Publication history

Received by *Neurology: Neuroimmunology & Neuroinflammation* October 8, 2018. Accepted in final form December 7, 2018.

References

1. Baumann M, Sahin K, Lechner C, et al. Clinical and neuroradiological differences of paediatric acute disseminating encephalomyelitis with and without antibodies to the myelin oligodendrocyte glycoprotein. *J Neurol Neurosurg Psychiatry* 2015;86:265–272.
2. Brilot F, Dale RC, Selzer RC, et al. Antibodies to native myelin oligodendrocyte glycoprotein in children with inflammatory demyelinating central nervous system disease. *Ann Neurol* 2009;66:833–842.
3. Sato DK, Callegaro D, Lana-Peixoto MA, et al. Distinction between MOG antibody-positive and AQP4 antibody-positive NMO spectrum disorders. *Neurology* 2014;82:474–481.
4. Höftberger R, Sepúlveda M, Armangue T, et al. Antibodies to MOG and AQP4 in adults with neuromyelitis optica and suspected limited forms of the disease. *Mult Scler* 2015;21:866–874.
5. Kitley J, Waters P, Woodhall M, et al. Neuromyelitis optica spectrum disorders with aquaporin-4 and myelin-oligodendrocyte glycoprotein antibodies: a comparative study. *JAMA Neurol* 2014;71:276–283.
6. Jurynczyk M, Messina S, Woodhall MR, et al. Clinical presentation and prognosis in MOG-antibody disease: a UK study. *Brain* 2017;140:3128–3138.
7. Sepúlveda M, Armangue T, Martínez-Hernández E, et al. Clinical spectrum associated with MOG autoimmunity in adults: significance of sharing rodent MOG epitopes. *J Neurol* 2016;263:1349–1360.
8. Hamid SHM, Whittam D, Saviour M, et al. Seizures and encephalitis in myelin oligodendrocyte glycoprotein IgG disease vs aquaporin 4 IgG disease. *JAMA Neurol* 2018;75:65–71.
9. Ogawa R, Nakashima I, Takahashi T, et al. MOG antibody-positive, benign, unilateral, cerebral cortical encephalitis with epilepsy. *Neurol Neuroimmunol Neuroinflamm* 2017;4:e322. doi: 10.1212/NXI.0000000000000322.
10. Cobo-Calvo A, Ruiz A, Maillart E, et al. Clinical spectrum and prognostic value of CNS MOG autoimmunity in adults: the MOGADOR study. *Neurology* 2018;90:e1858–e1869.
11. Di Pauli F, Höftberger R, Reindl M, et al. Fulminant demyelinating encephalomyelitis: insights from antibody studies and neuropathology. *Neurol Neuroimmunol Neuroinflamm* 2015;2:e175. doi: 10.1212/NXI.0000000000000175.

12. Cobo-Calvo A, Ruiz A, D'Indy H, et al. MOG antibody-related disorders: common features and uncommon presentations. *J Neurol* 2017;264:1945–1955.
13. Marignier R, Bernard-Valnet R, Giraudon P, et al. Aquaporin-4 antibody-negative neuromyelitis optica: distinct assay sensitivity-dependent entity. *Neurology* 2013;80:2194–2200.
14. Mader S, Gredler V, Schanda K, et al. Complement activating antibodies to myelin oligodendrocyte glycoprotein in neuromyelitis optica and related disorders. *J Neuroinflammation* 2011;8:184.
15. Boronat A, Sabater L, Saiz A, Dalmau J, Graus F. GABA(B) receptor antibodies in limbic encephalitis and anti-GAD-associated neurologic disorders. *Neurology* 2011;76:795–800.
16. Bitoun S, Roques P, Larcher T, et al. Both systemic and intra-articular immunization with citrullinated peptides are needed to induce arthritis in the macaque. *Front Immunol* 2017;8:1816.
17. Stimmer L, Fovet CM, Serguera C. Experimental models of autoimmune demyelinating diseases in nonhuman primates. *Vet Pathol* 2018;55:27–41.
18. Marignier R, Ruiz A, Cavagna S, et al. Neuromyelitis optica study model based on chronic infusion of autoantibodies in rat cerebrospinal fluid. *J Neuroinflammation* 2016;13:111.
19. Peker S, Kurtkaya O, Uziun I, Pamir MN. Microanatomy of the central myelin-peripheral myelin transition zone of the trigeminal nerve. *Neurosurgery* 2006;59:354–359.
20. Pamir HA. Some histologic features of the cranial nerves. *Arch Neurol Psychiatry* 1931;25:356–372.
21. Fraher JP, Smiddy PF, O'Sullivan VR. The central-peripheral transitional regions of cranial nerves. Trochlear and abducent nerves. *J Anat* 1988;161:115–123.
22. von Büdingen HC, Tanuma N, Villoslada P, Ouallet SL, Hauser SL, Genain CP. Immune responses against the myelin/oligodendrocyte glycoprotein in experimental autoimmune demyelination. *J Clin Immunol* 2001;21:155–170.
23. Peschl P, Schanda K, Zeka B, et al. Human antibodies against the myelin oligodendrocyte glycoprotein can cause complement-dependent demyelination. *J Neuroinflammation* 2017;14:208.
24. Mayer MC, Breithaupt C, Reindl M, et al. Distinction and temporal stability of conformational epitopes on myelin oligodendrocyte glycoprotein recognized by patients with different inflammatory central nervous system diseases. *J Immunol* 2013;191:3594–3604.
25. Marta CB, Oliver AR, Sweet RA, Pfeiffer SE, Ruddle NH. Pathogenic myelin oligodendrocyte glycoprotein antibodies recognize glycosylated epitopes and perturb oligodendrocyte physiology. *Proc Natl Acad Sci USA* 2005;102:13992–13997.
26. Delarasse C, Della Gaspera B, Lu CW, et al. Complex alternative splicing of the myelin oligodendrocyte glycoprotein gene is unique to human and non-human primates. *J Neurochem* 2006;98:1707–1717.
27. Warabi Y, Yamazaki M, Shimizu T, Nagao M. Abnormal nerve conduction study findings indicating the existence of peripheral neuropathy in multiple sclerosis and neuromyelitis optica. *Biomed Res Int* 2013;2013:847670.
28. Nagao M, Suzuki H, Ichihashi J, et al. Acute combined central and peripheral demyelination showing anti-aquaporin 4 antibody positivity. *Intern Med* 2012;51:2443–2447.
29. Kim S, Park J, Kwon BS, et al. Radiculopathy in neuromyelitis optica: how does anti-AQP4 Ab involve PNS? *Mult Scler Relat Disord* 2017;18:77–81.
30. Takai Y, Misu T, Nakashima I, et al. Two cases of lumbosacral myeloradiculitis with anti-aquaporin-4 antibody. *Neurology* 2012;79:1826–1828.
31. Mingbunjerdsuk P, Katirji B. Acute cervical segmental denervation in neuromyelitis optica spectrum disorder. *J Clin Neuromuscul Dis* 2014;16:90–97.
32. Laemmer AB, Maihöfner C, Göllitz P, et al. Possible second motor neuron damage in neuromyelitis optica. *Clin Neurophysiol* 2014;125:859–861.
33. Bonnan M, Cabre P. Meningeal and vestibulocochlear nerve enhancement in neuromyelitis optica. *Eur J Neurol* 2017;24:e89–e90.
34. van der Meijs AH, Tan IL, Barkhof F. Incidence of enhancement of the trigeminal nerve on MRI in patients with multiple sclerosis. *Mult Scler* 2002;8:64–67.
35. da Silva CJ, da Rocha AJ, Mendes MF, et al. Trigeminal involvement in multiple sclerosis: magnetic resonance imaging findings with clinical correlation in a series of patients. *Mult Scler* 2005;11:282–285.
36. Pichiecchio A, Bergamaschi R, Tavazzi E, et al. Bilateral trigeminal enhancement on magnetic resonance imaging in a patient with multiple sclerosis and trigeminal neuralgia. *Mult Scler* 2007;13:814–816.
37. Shor N, Amador MD, Dormont D, et al. Involvement of peripheral III nerve in multiple sclerosis patient: report of a new case and discussion of the underlying mechanism. *Mult Scler* 2017;23:748–750.

Neurology[®] Neuroimmunology & Neuroinflammation

Cranial nerve involvement in patients with MOG antibody–associated disease

Alvaro Cobo-Calvo, Xavier Ayrignac, Philippe Kerschen, et al.

Neurol Neuroimmunol Neuroinflamm 2019;6;

DOI 10.1212/NXI.0000000000000543

This information is current as of February 1, 2019

Updated Information & Services	including high resolution figures, can be found at: http://nn.neurology.org/content/6/2/e543.full.html
References	This article cites 37 articles, 3 of which you can access for free at: http://nn.neurology.org/content/6/2/e543.full.html##ref-list-1
Permissions & Licensing	Information about reproducing this article in parts (figures, tables) or in its entirety can be found online at: http://nn.neurology.org/misc/about.xhtml#permissions
Reprints	Information about ordering reprints can be found online: http://nn.neurology.org/misc/addir.xhtml#reprintsus

Neurol Neuroimmunol Neuroinflamm is an official journal of the American Academy of Neurology. Published since April 2014, it is an open-access, online-only, continuous publication journal. Copyright Copyright © 2019 The Author(s). Published by Wolters Kluwer Health, Inc. on behalf of the American Academy of Neurology.. All rights reserved. Online ISSN: 2332-7812.

