

Michelle Hilderink, MD
Maarten J. Titulaer, MD,
PhD
Marco W.J. Schreurs,
PhD
Koos Keizer, MD, PhD
Jan Erik H. Bunt, MD,
PhD

*Neurol Neuroimmunol
Neuroinflamm*
2015;2:e126; doi: 10.1212/
NXI.000000000000126

TRANSIENT ANTI-NMDAR ENCEPHALITIS IN A NEWBORN INFANT DUE TO TRANSPLACENTAL TRANSMISSION

OPEN

A 20-year-old woman developed anti-NMDA receptor (NMDAR) encephalitis with psychosis, dysphagia, hemiparesis, generalized dystonia, cortical blindness, and status epilepticus. IgG NMDAR antibodies were present in serum and CSF (figure). She was successfully treated with IV immunoglobulin (IVIg), plasmapheresis, and carbamazepine. She relapsed 1.5 years later and was treated regularly with IVIg and carbamazepine since that time. She became pregnant 2.5 years after the relapse. There were some remaining cognitive deficits, but she had been stable since the relapse. At 37 weeks of gestation a boy was born, weighing 2.5 kg. At birth, he responded little to manual stimulation and had respiratory insufficiency. The Moro, rooting, grasp, sucking, and swallowing reflexes were decreased or absent but his muscle tone was normal. He did not respond to venous cannulation. The infant remained lethargic and required supplemental oxygen and gastric tube feeding. He received IV antibiotics for 3 days. At day 6 he opened his eyes for the first time and slowly started bottle drinking. Because the infant improved after several days, no lumbar puncture was performed. By day 10 his feeding problems had resolved.

Because the clinical symptoms of the neonate could be due to several causes, an extended diagnostic workup was performed, including liver, kidney, and thyroid function; infection and coagulation parameters; blood gas; glucose; ammonia in blood; cytomegalovirus in urine; and cerebral ultrasound. No abnormalities were found. The neonatal carbamazepine plasma concentration was very low (1.1 mg/L). Without any improvement on day 3, we ordered serum NMDAR antibodies, which returned positive by cell-based assay (CBA; EuroImmun, Lübeck, Germany), immunohistochemistry, and live hippocampal neurons, confirming the diagnosis of anti-NMDAR encephalitis (figure). NMDAR antibodies were no longer detectable by immunohistochemistry and were weakly positive by CBA at 3 months and 1 year. At 12 months his development was normal.

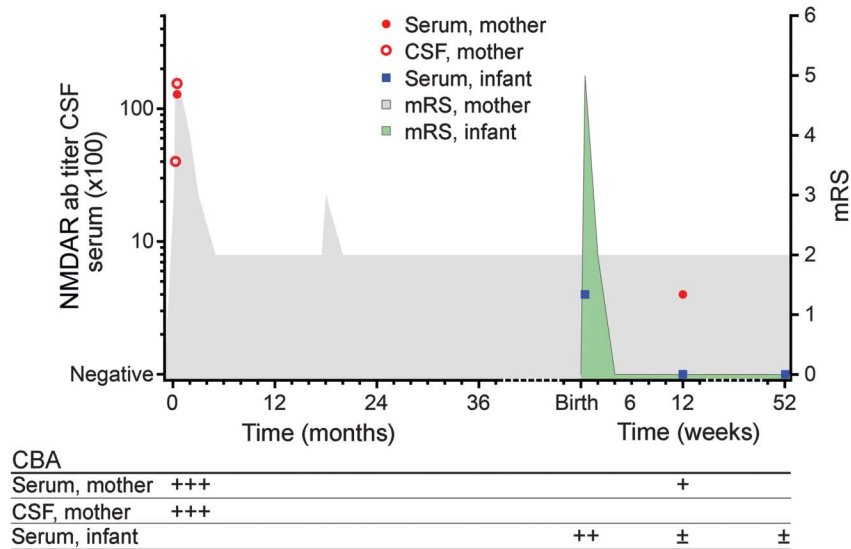
Anti-NMDAR encephalitis is an autoimmune disorder mediated by pathogenic NMDAR antibodies.¹ It

can occur at all ages (median age 19) and has been reported in pregnant women.^{2–5} Maternal IgG antibodies can cross the placenta and cause diseases in newborn infants. We report a case of a newborn with anti-NMDAR encephalitis due to intrauterine transfer of maternal NMDAR antibodies in a mother without active clinical symptoms 4 years after her disease.

Maternal antibodies of subtype IgG1 and IgG3 can cross the placenta from weeks 14–16 of pregnancy and cause autoimmune newborn diseases.⁶ It is known that in many maternal autoimmune diseases, such as Graves disease, systemic lupus erythematosus, and myasthenia gravis, the newborn infant remains asymptomatic during pregnancy. These women deliver in the hospital to monitor both mother and child. Only 6 newborn infants from mothers with acute anti-NMDAR encephalitis during pregnancy have been described. Five of these infants did not have neurologic symptoms.⁴ In 2 infants antibody tests were performed, which were negative. In the only symptomatic infant, the mother developed acute anti-NMDAR encephalitis in the second month of pregnancy and remained severely ill in the intensive care unit.⁵ She had severely fluctuating blood pressures and uteroplacental hemodynamics, leading to uteroplacental insufficiency. She delivered spontaneously at 34 weeks of gestation and died 2 weeks later due to complications of her illness. The newborn had neurologic symptoms and transient serum anti-NMDAR antibodies, and the child had a developmental delay at 3 years of age with cortical dysplasia on the cerebral MRI. In that report, it is impossible to distinguish between the effects of maternal illness and the effect of maternally derived NMDAR antibodies. The critical period in utero combined with prematurity could have resulted in the cerebral MRI lesions and the neurologic sequelae.⁵

In our case, the mother was in good condition before, during, and after pregnancy. After the difficult neonatal period, the infant developed well. To exclude false-positive results reported in CBAs using serum testing only, we performed immunohistochemistry showing the characteristic hippocampal staining and positive live hippocampal neuron staining. In combination with the clinical presentation, we diagnosed anti-NMDAR encephalitis.⁷ Therefore, we did not perform a lumbar puncture.

Figure Clinical course and CSF/serum NMDA receptor (NMDAR) antibody (ab) titers of mother and infant



Titers were measured with immunohistochemistry of rat brain as described before.⁷ Broken x-axis represents a change of units from months to weeks at the birth of the infant. Circles and boxes represent titers (left y-axis), and the shaded areas represent the clinical course (right y-axis; light gray = mother, light green = infant) using the modified Rankin Scale (mRS) (0 = normal, 1 = no disability, 2 = slight disability, 3 = moderate disability, 4 = moderately severe disability, 5 = severe disability, bedridden, 6 = dead). CBA = cell-based assay.

The clinical symptoms related to anti-NMDAR encephalitis can mimic many neonatal conditions, such as prematurity, infection, asphyxia, medication-related side effects, maternal substance abuse, pulmonary diseases, and neurologic diseases. Because anti-NMDAR encephalitis occurs frequently in adolescents and young women, risk assessment of pregnancy is necessary.² Most patients will remain antibody-positive in serum and CSF after recovery.⁷ This case illustrates that asymptomatic pregnant women with low antibody titers and without any symptoms can deliver symptomatic neonates. Testing NMDAR antibodies in pregnant women with a history of anti-NMDAR encephalitis is recommended. If antibodies are present, we recommend clinical monitoring of the neonate during and after birth.

From the Department of Pediatrics (M.H., J.E.H.B.) and Department of Neurology (K.K.), Catharina Hospital, Eindhoven, the Netherlands; Department of Neurology (M.J.T.) and Department of Immunology (M.W.J.S.), Erasmus Medical Center, Rotterdam, the Netherlands; and Department of Pediatrics (J.E.H.B.), Elisabeth-TweeSteden, Tilburg, the Netherlands.

Author contributions: Michelle Hilderink: drafting/ revising the manuscript, study concept or design. Maarten J. Titulaer: drafting/ revising the manuscript, analysis or interpretation of data, acquisition of data. Marco W.J. Schreurs: drafting/ revising the manuscript, analysis or interpretation of data, acquisition of data. Koos Keizer: drafting/ revising the manuscript, analysis or interpretation of data, acquisition of data. Jan Erik H. Bunt: drafting/ revising the manuscript, study concept or design, analysis or interpretation of data, acquisition of data.

Study funding: No targeted funding reported.

Disclosure: M. Hilderink reports no disclosures. M.J. Titulaer serves on the scientific advisory board of MedImmune LLC, received travel funding from Sun Pharma, is on the editorial board for Neurology: Neuroimmunology & Neuroinflammation, and received research support from Netherlands Organisation for Scientific

Research, ErasmusMC, and Duth Epilepsy Foundations. M.W.J. Schreurs, K. Keizer, and J.E.H. Bunt report no disclosures. Go to Neurology.org/nn for full disclosure forms. The Article Processing Charge was paid by the authors.

This is an open access article distributed under the terms of the Creative Commons Attribution-NonCommercial-NoDerivatives License 4.0 (CC BY-NC-ND), which permits downloading and sharing the work provided it is properly cited. The work cannot be changed in any way or used commercially.

Received March 25, 2015. Accepted in final form May 14, 2015.

Correspondence to Dr. Hilderink: michelle.hilderink@catharinaziekenhuis.nl

- Dalmaj J, Tüzün E, Wu HY, et al. Paraneoplastic anti-N-methyl-D-aspartate receptor encephalitis associated with ovarian teratoma. *Ann Neurol* 2007;61:25–36.
- Titulaer M, McCracken L, Gabilondo I, et al. Treatment and prognostic factors for long-term outcome in patients with anti-NMDA receptor encephalitis: an observational cohort study. *Lancet Neurol* 2013;12:157–165.
- Kumar MA, Jain A, Dechant VE, et al. Anti-N-methyl-D-aspartate receptor encephalitis during pregnancy. *Arch Neurol* 2010;67:884–887.
- Goldberg EM, Titulaer M, de Blank PM, Sievert A, Ryan N. Anti-N-methyl-D-aspartate receptor-mediated encephalitis in infants and toddlers: case report and review of the literature. *Pediatr Neurol* 2014;50:181–184.
- Jagota P, Vincent A, Bhidayasiri R. Transplacental transfer of NMDA receptor antibodies in an infant with cortical dysplasia. *Neurology* 2014;82:1662–1663.
- Brucato A, Doria A, Frassi M, et al. Pregnancy outcome in 100 women with autoimmune diseases and anti-Ro/SSA antibodies: a prospective controlled study. *Lupus* 2002;11:716–721.
- Gresa-Arribas N, Titulaer M, Torrents A, et al. Antibody titres at diagnosis and during follow-up of anti-NMDA receptor encephalitis: a retrospective study. *Lancet Neurol* 2014;13:167–177.

Neurology[®] Neuroimmunology & Neuroinflammation

Transient anti-NMDAR encephalitis in a newborn infant due to transplacental transmission

Michelle Hilderink, Maarten J. Titulaer, Marco W.J. Schreurs, et al.
Neurol Neuroimmunol Neuroinflamm 2015;2;
DOI 10.1212/NXI.0000000000000126

This information is current as of June 18, 2015

Neurol Neuroimmunol Neuroinflamm is an official journal of the American Academy of Neurology. Published since April 2014, it is an open-access, online-only, continuous publication journal. Copyright © 2015 American Academy of Neurology. All rights reserved. Online ISSN: 2332-7812.



Updated Information & Services	including high resolution figures, can be found at: http://nn.neurology.org/content/2/4/e126.full.html
References	This article cites 7 articles, 0 of which you can access for free at: http://nn.neurology.org/content/2/4/e126.full.html##ref-list-1
Citations	This article has been cited by 2 HighWire-hosted articles: http://nn.neurology.org/content/2/4/e126.full.html##otherarticles
Subspecialty Collections	This article, along with others on similar topics, appears in the following collection(s): All Immunology http://nn.neurology.org/cgi/collection/all_immunology All Pediatric http://nn.neurology.org/cgi/collection/all_pediatic Autoimmune diseases http://nn.neurology.org/cgi/collection/autoimmune_diseases Clinical neurology examination http://nn.neurology.org/cgi/collection/clinical_neurology_examination
Permissions & Licensing	Information about reproducing this article in parts (figures,tables) or in its entirety can be found online at: http://nn.neurology.org/misc/about.xhtml#permissions
Reprints	Information about ordering reprints can be found online: http://nn.neurology.org/misc/addir.xhtml#reprintsus

Neurol Neuroimmunol Neuroinflamm is an official journal of the American Academy of Neurology. Published since April 2014, it is an open-access, online-only, continuous publication journal. Copyright © 2015 American Academy of Neurology. All rights reserved. Online ISSN: 2332-7812.

