

Takuya Uehara, MD  
Goichi Beck, MD  
Kousuke Baba, MD  
Masahito Mihara, MD  
Tatsusada Okuno, MD  
Hisae Sumi, MD  
Yuji Nakatsuji, MD  
Hideki Mochizuki, MD

*Neurol Neuroimmunol  
Neuroinflamm*  
2016;3:e230; doi: 10.1212/  
NXL.0000000000000230

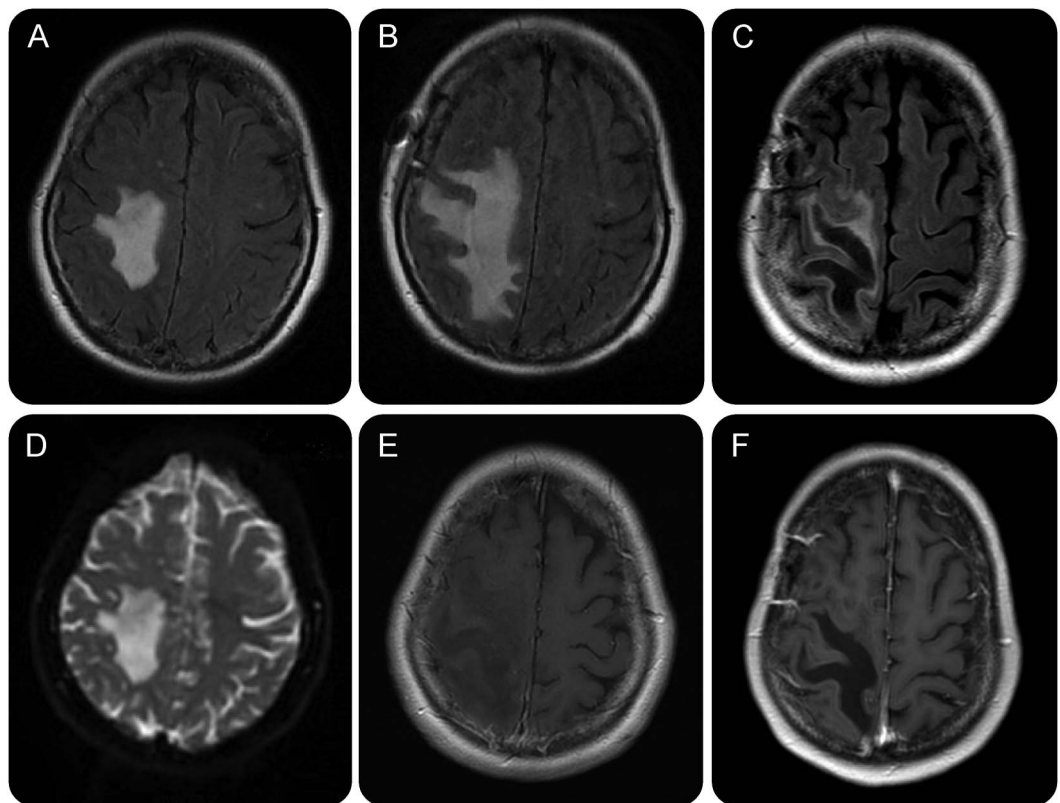
## TUMEFACTIVE BRAIN LESION WITH RAPID CAVITY FORMATION ASSOCIATED WITH ANTI-AQUAPORIN-4 ANTIBODY

### OPEN

A 54-year-old woman with no medical history presented with left hemiparesis and hemianopsia. Brain MRI showed an extensive lesion without enhancement in the right parietal lobe, followed by rapid cavity formation (figure 1). Brain biopsy performed 55 days after disease onset revealed decreased glial fibrillary acidic protein and aquaporin-4 (AQP4) immunoreactivity, though we could not show the activated complement due to the paucity of the sample (figure 2).

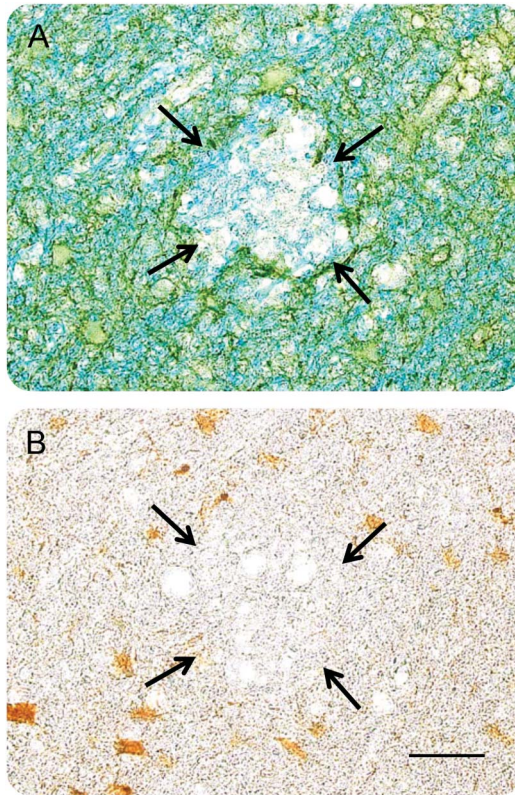
Brain biopsy results revealed that the patient was positive for anti-AQP4 antibody. She received methylprednisolone pulse therapy, followed by plasmapheresis. Progression was inhibited. Based on anti-AQP4 antibody-seropositive cases, the concept of neuromyelitis optica spectrum disorders is becoming broader.<sup>1</sup> These disorders should be considered in differential diagnoses when tumefactive brain lesions are observed.<sup>2</sup> Our case highlights the importance of examining AQP4 immunoglobulin G, because it could result in an early diagnosis without performing biopsy.<sup>3</sup>

**Figure 1** MRI of the brain



Noncontrast fluid-attenuated inversion recovery images on days 2 (A), 8 (B), and 35 (C). Note extensive cavity formation on day 35. The lesion shows high intensity on an apparent diffusion coefficient map on day 2 (D). Enhanced T1-weighted images on days 3 (E) and 35 (F) show no enhancement.

**Figure 2** Brain biopsy



(A) Double staining with anti-aquaporin-4 (AQP4) antibody (dark green) and Luxol fast blue (blue) is shown. Loss of AQP4 immunoreactivity with myelin pallor is shown (surrounded by arrows). (B) Staining with glial fibrillary acidic protein (GFAP) (brown) is shown. Loss of GFAP immunoreactivity is observed in the corresponding area shown in A (surrounded by arrows). Scale bar: 50  $\mu$ m.

From the Department of Neurology, Osaka University Graduate School of Medicine, Japan.

*Author contributions:* Drafting of manuscript: Takuya Uehara, Yuji Nakatsuji. Immunohistochemical analysis: Goichi Beck, Hisae Sumi. Analysis and interpretation of data: Kousuke Baba, Masahito Mihara, Tatsusada Okuno. Critical revision of the manuscript: Hideki Mochizuki.

*Study funding:* No targeted funding reported.

*Disclosure:* The authors report no disclosures. Go to [Neurology.org/nn](http://Neurology.org/nn) for full disclosure forms. The Article Processing Charge was paid by the authors.

This is an open access article distributed under the terms of the Creative Commons Attribution-NonCommercial-NoDerivatives License 4.0 (CC BY-NC-ND), which permits downloading and sharing the work provided it is properly cited. The work cannot be changed in any way or used commercially.

Received January 7, 2016. Accepted in final form March 16, 2016.

Correspondence to Dr. Mochizuki: [hmochizuki@neuro.med.osaka-u.ac.jp](mailto:hmochizuki@neuro.med.osaka-u.ac.jp)

1. Wingerchuk DM, Banwall B, Bennett JL, et al. International consensus diagnostic criteria for neuromyelitis optica spectrum disorders. *Neurology* 2015;85:177–189.
2. Kim HJ, Kim W, Kim SH, et al. Brain abnormalities as an initial manifestation of neuromyelitis optica spectrum disorder. *Mult Scler* 2011;17:1107–1112.
3. Popescu BF, Guo Y, Jentft JE, et al. Diagnostic utility of aquaporin-4 in the analysis of active demyelinating lesions. *Neurology* 2015;84:148–158.

# Neurology<sup>®</sup> Neuroimmunology & Neuroinflammation

## **Tumefactive brain lesion with rapid cavity formation associated with anti-aquaporin-4 antibody**

Takuya Uehara, Goichi Beck, Kousuke Baba, et al.  
*Neurol Neuroimmunol Neuroinflamm* 2016;3;  
DOI 10.1212/NXI.0000000000000230

**This information is current as of April 14, 2016**

<b>Updated Information &amp; Services</b>	including high resolution figures, can be found at: <a href="http://nn.neurology.org/content/3/3/e230.full.html">http://nn.neurology.org/content/3/3/e230.full.html</a>
<b>References</b>	This article cites 3 articles, 0 of which you can access for free at: <a href="http://nn.neurology.org/content/3/3/e230.full.html##ref-list-1">http://nn.neurology.org/content/3/3/e230.full.html##ref-list-1</a>
<b>Subspecialty Collections</b>	This article, along with others on similar topics, appears in the following collection(s): <b>All Demyelinating disease (CNS)</b> <a href="http://nn.neurology.org/cgi/collection/all_demyelinating_disease_cns">http://nn.neurology.org/cgi/collection/all_demyelinating_disease_cns</a> <b>Autoimmune diseases</b> <a href="http://nn.neurology.org/cgi/collection/autoimmune_diseases">http://nn.neurology.org/cgi/collection/autoimmune_diseases</a> <b>MRI</b> <a href="http://nn.neurology.org/cgi/collection/mri">http://nn.neurology.org/cgi/collection/mri</a>
<b>Permissions &amp; Licensing</b>	Information about reproducing this article in parts (figures, tables) or in its entirety can be found online at: <a href="http://nn.neurology.org/misc/about.xhtml#permissions">http://nn.neurology.org/misc/about.xhtml#permissions</a>
<b>Reprints</b>	Information about ordering reprints can be found online: <a href="http://nn.neurology.org/misc/addir.xhtml#reprintsus">http://nn.neurology.org/misc/addir.xhtml#reprintsus</a>

*Neurol Neuroimmunol Neuroinflamm* is an official journal of the American Academy of Neurology. Published since April 2014, it is an open-access, online-only, continuous publication journal. Copyright © 2016 American Academy of Neurology. All rights reserved. Online ISSN: 2332-7812.

