

Michael R. Pranzatelli,  
MD  
Nathan R. McGee, BS  
Zeng Y. Wang, MD  
Brajesh K. Agrawal, MD

*Neurol Neuroimmunol  
Neuroinflamm*  
2017;4:e316; doi: 10.1212/  
NXI.0000000000000316

## CHARACTERISTICS AND PHARMACODYNAMICS OF SEVERE NEUROINFLAMMATION IN A CHILD WITH NEUROLUPUS

### OPEN

Pediatric-onset systemic lupus erythematosus (SLE) encompasses diverse symptoms, such as headache, seizures, stroke, depression, psychosis, cognitive impairment, chorea, and neuropathy.<sup>1</sup> Neuropsychiatric lupus occurs in one-fourth of cases.<sup>1</sup> Although 95%–97% of the children survive, the disease flares in childhood in 20%, and 25% sustain permanent neuropsychiatric injury.<sup>1</sup> The paucity of biomarkers, mostly studied in blood<sup>2,3</sup>; lack of modern neuroimmunologic studies; and poorly defined treatment modalities have hindered management.<sup>4</sup> We describe a child with extensive peripheral and CNS manifestations and multiorgan involvement. Multiple cellular and cytokine/chemokine markers indicated profound neuroinflammation with some components responsive, others resistant, to 3-agent immunotherapy.

**Methods.** Description of the laboratory methods is provided at [Neurology.org/nn](http://Neurology.org/nn).

**Case report.** A previously healthy 11-year-old African American girl was hospitalized for intractable headaches, myalgias, malar rash, intermittent paresthesias, foot drop, and 25-pound weight loss over 5 months. SLE was diagnosed based on speckled antinuclear antibodies >1:640, DNA-DS 257 IU/mL, anti-histone 321 U/mL, and anti-Smith 386 U/mL. CSF studies revealed high total immunoglobulin G (IgG) and IgG synthesis rate (table e-1). Head MRI disclosed transient fluid-attenuated inversion recovery T2 hyperintensities and mild cerebral atrophy (figure e-1). EMG/nerve conduction studies (NCS) exhibited sensorimotor neuropathy, conduction block at the fibular head, and absent F-waves and H-reflex, suggesting acute demyelinating peripheral polyneuropathy. Classical features of acute inflammatory demyelinating polyneuropathy, such as acute ascending radiculopathy, cranial nerve involvement, respiratory compromise, and albuminocytologic dissociation, were absent. Other abnormalities included membranous lupus nephritis (International Society of Nephrology/Renal Pathology Society class V), a small pericardial effusion, leukopenia, anemia, and thrombocytopenia.

The hospital course was protracted due to acute psychosis, severe agitation, dystonic postures, tonic-clonic seizures, status epilepticus (week 5), and chorea. The patient was treated with IV pulse methylprednisolone (20 mg/kg/d × 3 days) on weeks 1 and 6; oral methylprednisolone 1 mg/kg/d; IV phenobarbital and fosphenytoin; IV cyclophosphamide (750 mg/m<sup>2</sup>) on weeks 2, 7, and 9; and IV immunoglobulin (IVIg) (1 g/kg/d for 2 days) on weeks 3, 6, and 8. She made durable clinical gains from week 7–12, and the MRI brain lesions had resolved, but the second EMG/NCS at 8 weeks showed no improvement and significant axonal loss (table e-2). At discharge on prednisone, the patient spoke in short sentences and took several steps without assistance. Four months later, EEG showed mild encephalopathy.

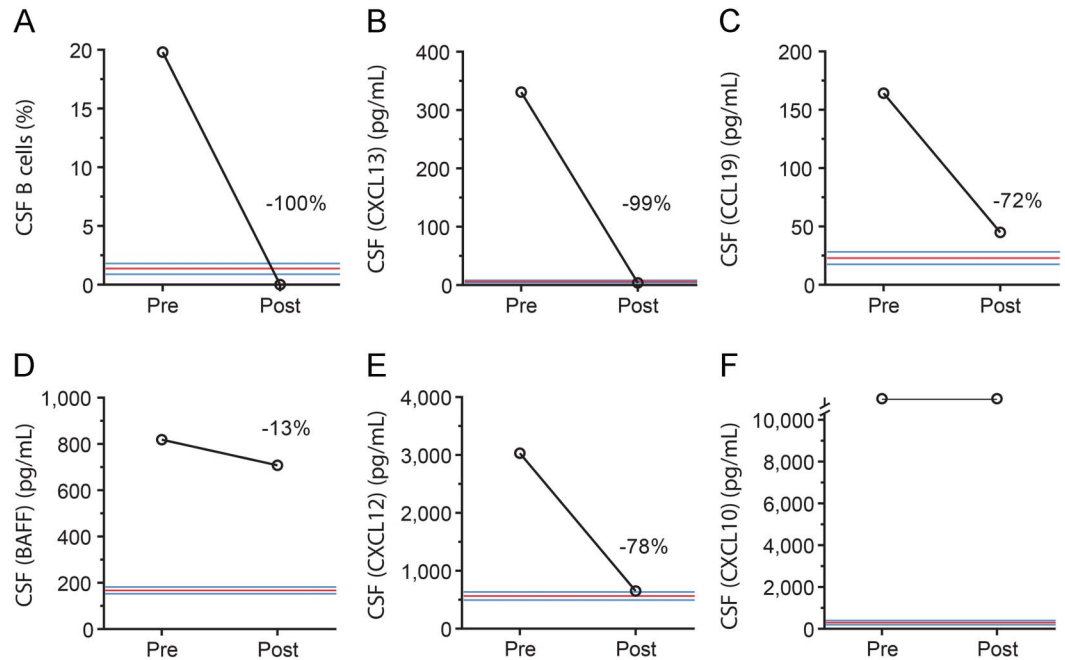
**Results. Neuroimmunologic studies.** In CSF (figure 1), pretreatment inflammatory cytokine/chemokine concentrations were strikingly elevated: CXCL13 (331-fold), CCL19 (15-fold), BAFF (5.7-fold), CXCL12 (5.2-fold), CXCL10 (>143-fold), interleukin-6 (IL-6) (7.4-fold). The CSF/serum ratio was raised at 0.17 for CXCL13 (controls 0.01) and >1.2 for CXCL10 (controls 0.65), indicating intrathecal chemokine secretion. In serum, CXCL13 (23-fold) and CXCL10 (88-fold) concentrations were marked, less so for CCL21 (1.5-fold), whereas CCL17 was low (–88%).

After 6 weeks of immunotherapy, the 13-fold elevated CSF B-cell frequency and high concentration of CXCL13, CXCL12, and CCL19 plunged to the control median, but BAFF and CXCL10 remained elevated. Increased T-cytotoxic/suppressor cell frequency and reduced T-helper/inducer frequency lowered the T-helper (Th)/T-suppressor ratio (table e-1). The initially elevated natural killer cell percentage decreased. CSF IL-6 plummeted 93% from 13.3 to 0.95 pg/mL (controls 0–7.5). Total IgG declined, the IgG synthesis rate remained elevated, and CSF leukocytosis abated.

**Discussion.** In this case of debilitating pediatric neurolupus, the main findings were (1) major upregulation of CSF B cells and inflammatory cytokines/chemokines despite minimal pleocytosis and no oligoclonal bands; (2) evidence of increased Th1 and decreased Th2 immune responses, (3) incomplete prediction of CSF perturbations by blood testing; (4) downregulation of many, not all, clinical and

Supplemental data  
at [Neurology.org/nn](http://Neurology.org/nn)

**Figure 1** CSF inflammatory markers before and after treatment



(A) CD19+CD3<sup>-</sup> B cell frequency. (B) CXCL13 concentration. (C) CCL19 concentration. (D) BAFF concentration. (E) CXCL12 concentration. (F) CXCL10 concentration. CSF is normally analyzed undiluted, but even at a 1:20 dilution, the patient's massive CXCL10 concentration exceeded the highest concentration of standard. The control median and 95% confidence intervals from 18 to 25 children with noninflammatory neurologic disorders are shown in colored lines.

immunologic abnormalities on multimodal disease-modifying therapy; and (5) prolonged clinical and central/peripheral electrophysiologic recovery.

In CSF, the overexpression of lymphocyte chemoattractants (CXCL13, CCL19, CXCL12, CXCL10) and homeostatic cytokines (BAFF) may contribute to central B and T cell recruitment and proliferation/survival<sup>5</sup> in neurolupus. Lymphoid chemokines (CCL19, CXCL13) are relevant because they may form ectopic lymphoid structures within the CNS in chronic neuroinflammation.<sup>5</sup>

Posttreatment reduction in CSF B-cell frequency, CXCL13, CCL19, CXCL12, and IL-6 concentrations led to clinical improvement, whereas high BAFF and CXCL10 persisted despite it. CXCL10 is a potent inflammatory mediator in Th1 immune responses, induces migration of certain T-cell subsets,<sup>5</sup> and is involved in lupus nephritis.<sup>6</sup> The extreme CSF CXCL10 elevation is similar to that in adult-onset SLE.<sup>7</sup>

In serum, SLE-induced reduction in CCL17, which attracts CXCR4-bearing Th2 cells, is consistent with suppressed expression of CCL17 in lupus-prone MRL/lpr mice.<sup>3</sup> Increased CCL21 would recruit distinct T- and B-cell subpopulations by binding to CXCR7, as does CCL19.<sup>5</sup> Serum CXCL13 and CXCL10 were predictably elevated.<sup>3,4,7</sup>

Multiagent immunotherapy prevents isolating the effect of any one agent. However, from our research in a paraneoplastic disorder, high-dose glucocorticoids

probably account for the corrective effects on chemokines/cytokines. Immune cellular phenotypic changes are most likely attributable to cyclophosphamide. IVIg has neither effect, but modulates antibodies and unmeasured parameters.

These findings, requiring confirmation in other children with neurolupus, have clinical implications. CSF lymphocyte subset analysis, available at hospital flow cytometry laboratories, characterized neuroinflammation and raised the level of alert more clearly than routine CSF studies. No one finding was specific for neurolupus, but the combined immunology panel showed commonalities and differences compared to multiple sclerosis and paraneoplastic disorders. It can be incorporated into translational research on pediatric neurolupus to identify biomarkers of disease activity, treatment response, or prognosis.<sup>2</sup> CSF posttreatment testing for no evidence of disease activity addresses questions about the type and duration of immunotherapy. Because swift and sufficient handling of neuroinflammation is crucial, more rapid, brain-directed targeting of the B-cell/humoral component should be considered in the initial therapeutic approach.

*From the National Pediatric Neuroinflammation Organization, Inc. (M.R.P., N.R.M.), Orlando, FL; Department of Neurology, University of Louisville (Z.Y.W.), KY; and Department of Neurology, Santa Clara Valley Medical Center (B.K.A.), San Jose, CA.*

*Author contributions: M.R.P. conceived and designed the laboratory experiments, N.R.M. performed the experiments, and M.R.P. and N.R.M. analyzed the data. M.R.P. and B.K.A. defined the patient,*

*B.K.A. wrote the case report, and M.R.P. wrote the manuscript. Z.Y.W. performed and analyzed the electrophysiologic studies. All authors reviewed/revise and finalized the manuscript prior to submission.*

*Acknowledgment: The authors thank the patient, her family, and the other treating physicians, including Dr. Hossam H. AbdelSalam, Dr. Jane K. Taylor, and Dr. Gurpreet S. Mander.*

*Study funding: No targeted funding.*

*Disclosure: The authors report no disclosures. Go to [Neurology.org/nn](http://Neurology.org/nn) for full disclosure forms. The Article Processing Charge was paid by the authors.*

*This is an open access article distributed under the terms of the Creative Commons Attribution-NonCommercial-NoDerivatives License 4.0 (CC BY-NC-ND), which permits downloading and sharing the work provided it is properly cited. The work cannot be changed in any way or used commercially without permission from the journal.*

*Received August 10, 2016. Accepted in final form November 3, 2016.*

*Correspondence to Dr. Pranzatelli: [omsusa@omsusa.org](mailto:omsusa@omsusa.org)*

1. Muscal E, Brey RL. Neurologic manifestations of systemic lupus erythematosus in children and adults. *Neurol Clin* 2010;28:61–73.

2. Kasama T, Odai T, Wakabayashi K, Yajima N, Miwa Y. Chemokines in systemic lupus erythematosus involving the central nervous system. *Front Biosci* 2008;13:2527–2536.
3. Ezzat M, El-Gammasy T, Shaheen K, Shokr E. Elevated production of serum B-cell-attracting chemokine-1 (BCA-1/CXCL13) is correlated with childhood-onset lupus disease activity, severity, and renal involvement. *Lupus* 2011;20:845–854.
4. Lee HT, Shiao YM, Wu TH, et al. Serum BLC/CXCL13 concentrations and renal expression of CXCL13/CXCR5 in patients with systemic lupus erythematosus and lupus nephritis. *J Rheumatol* 2010;37:45–52.
5. Ransohoff RM, Schafer D, Vincent A, Blachère NE, Bar-Or A. Neuroinflammation: ways in which the immune system affects the brain. *Neurotherapeutics* 2015;12:896–909.
6. Binder E, Edelbauer M. Use of biomarkers in the management of children with lupus. *Curr Rheumatol Rep* 2013;15:312.
7. Okamoto H, Iikuni N, Kamitsuji S, Yoshio T, Minota S, Kamatani N. IP-10/MCP-1 ratio in CSF is a useful diagnostic marker in neuropsychiatric lupus patients. *Rheumatology* 2006;45:232–234.

# Neurology<sup>®</sup> Neuroimmunology & Neuroinflammation

## Characteristics and pharmacodynamics of severe neuroinflammation in a child with neurolupus

Michael R. Pranzatelli, Nathan R. McGee, Zeng Y. Wang, et al.  
*Neurol Neuroimmunol Neuroinflamm* 2017;4;  
DOI 10.1212/NXI.0000000000000316

This information is current as of December 5, 2016

<b>Updated Information &amp; Services</b>	including high resolution figures, can be found at: <a href="http://nn.neurology.org/content/4/2/e316.full.html">http://nn.neurology.org/content/4/2/e316.full.html</a>
<b>Supplementary Material</b>	Supplementary material can be found at: <a href="http://nn.neurology.org/content/suppl/2016/12/05/4.2.e316.DC1">http://nn.neurology.org/content/suppl/2016/12/05/4.2.e316.DC1</a>
<b>References</b>	This article cites 7 articles, 1 of which you can access for free at: <a href="http://nn.neurology.org/content/4/2/e316.full.html##ref-list-1">http://nn.neurology.org/content/4/2/e316.full.html##ref-list-1</a>
<b>Subspecialty Collections</b>	This article, along with others on similar topics, appears in the following collection(s): <b>All Immunology</b> <a href="http://nn.neurology.org/cgi/collection/all_immunology">http://nn.neurology.org/cgi/collection/all_immunology</a> <b>Autoimmune diseases</b> <a href="http://nn.neurology.org/cgi/collection/autoimmune_diseases">http://nn.neurology.org/cgi/collection/autoimmune_diseases</a> <b>Lupus</b> <a href="http://nn.neurology.org/cgi/collection/lupus">http://nn.neurology.org/cgi/collection/lupus</a>
<b>Permissions &amp; Licensing</b>	Information about reproducing this article in parts (figures, tables) or in its entirety can be found online at: <a href="http://nn.neurology.org/misc/about.xhtml#permissions">http://nn.neurology.org/misc/about.xhtml#permissions</a>
<b>Reprints</b>	Information about ordering reprints can be found online: <a href="http://nn.neurology.org/misc/addir.xhtml#reprintsus">http://nn.neurology.org/misc/addir.xhtml#reprintsus</a>

*Neurol Neuroimmunol Neuroinflamm* is an official journal of the American Academy of Neurology. Published since April 2014, it is an open-access, online-only, continuous publication journal. Copyright Copyright © 2016 The Author(s). Published by Wolters Kluwer Health, Inc. on behalf of the American Academy of Neurology. All rights reserved. Online ISSN: 2332-7812.

