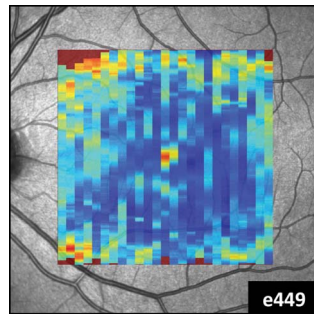
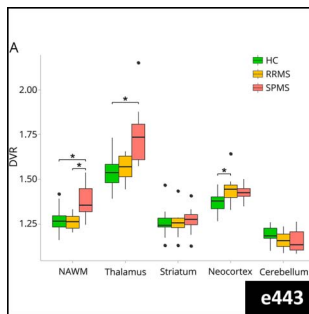
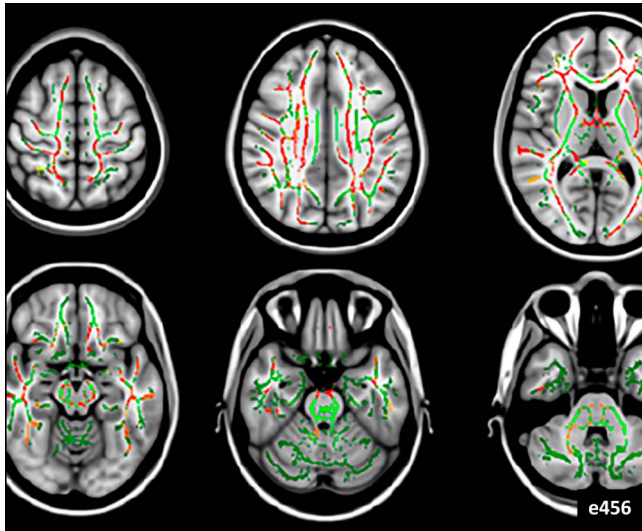### Editor's Corner

e461 **Looks can be deceiving: A B-cell-mediated encephalopathy with normal MRI?**

J. Dalmau

[Open Access](#)

### Editorial

e457 **Diagnosing MRI-negative autoimmune diseases**

C. Finke

[Open Access](#) [Companion article, p. e456](#)

### Articles

e456 **Normal brain imaging accompanies neuroimmunologically justified, autoimmune encephalomyelitis**

D. Takewaki, Y. Lin, W. Sato, H. Ono, M. Nakamura, M. Araki, T. Okamoto, Y. Takahashi, Y. Kimura, M. Ota, N. Sato, and T. Yamamura

[Open Access](#) [Editorial, p. e457](#)

e443 **Microglial activation, white matter tract damage, and disability in MS**

E. Rissanen, J. Tuisku, T. Vahlberg, M. Sucksdorff, T. Paavilainen, R. Parkkola, J. Rokka, A. Gerhard, R. Hinz, P.S. Talbot, J.O. Rinne, and L. Airas

[Open Access](#)

e446 **Treatment choices and neuropsychological symptoms of a large cohort of early MS**

O. von Bismarck, T. Dankowski, B. Ambrosius, N. Hessler, G. Antony, A. Ziegler, M.-M. Hoshi, L. Aly, F. Luessi, S. Groppa, L. Klotz, S.G. Meuth, B. Tackenberg, M. Stoppe, F. Then Bergh, H. Tumani, T. Kümpfel, M. Stangel, C. Heesen, B. Wildemann, F. Paul, A. Bayas, C. Warnke, F. Weber, R.A. Linker, U. Ziemann, U.K. Zettl, F. Zipp, H. Wiendl, B. Hemmer, R. Gold, and A. Salmen; On behalf of the German Competence Network Multiple Sclerosis (KKNMS)

[Open Access](#)

e449 **Multicenter reliability of semiautomatic retinal layer segmentation using OCT**

T. Oberwahrenbrock, G.L. Traber, S. Lukas, I. Gabilondo, R. Nolan, C. Songster, L. Balk, A. Petzold, F. Paul, P. Villoslada, A.U. Brandt, A.J. Green, and S. Schippling

[Open Access](#)

e450 **Thymectomy lowers the myasthenia gravis biomarker miR-150-5p**

C.J. Molin, L. Sabre, C.-A. Weis, T. Punga, and A.R. Punga

[Open Access](#)

e451 **Architectural B-cell organization in skeletal muscle identifies subtypes of dermatomyositis**

J. Radke, R. Koll, C. Preuße, D. Pehl, K. Todorova, C. Schönemann, Y. Allenbach, E. Aronica, M. de Visser, F.L. Heppner, J. Weis, S. Doostkam, T. Maisonobe, O. Benveniste, H.-H. Goebel, and W. Stenzel

[Open Access](#)

e452 **Symptomatic muscular sarcoidosis: Lessons from a nationwide multicenter study**

F. Cohen Aubart, S. Abbara, T. Maisonobe, V. Cottin, T. Papo, J. Haroche, A. Mathian, M. Pha, L. Gilardin, B. Hervier, M. Soussan, P. Morlat, H. Nunes, O. Benveniste, Z. Amoura, and D. Valeyre

[Open Access](#)

e453 **Rituximab before and during pregnancy: A systematic review, and a case series in MS and NMOSD**

G. Das, V. Damotte, J.M. Gelfand, C. Bevan, B.A.C. Cree, L. Do, A.J. Green, S.L. Hauser, and R. Bove

[Open Access](#)

### Clinical/Scientific Notes

e447 **Short-lasting unilateral neuralgiform headache attacks with cranial autonomic symptoms in NMOSD**

Y. Mizuno, K. Shinoda, M. Watanabe, T. Matsushita, R. Yamasaki, and J.-i. Kira

[Open Access](#)

e448 **Effective treatment of CLIPPERS with long-term use of rituximab**

V.P. Cipriani, N. Arndt, P. Pytel, A.T. Reder, and A. Javed

[Open Access](#)

e454 **Case of alopecia universalis associated with alemtuzumab treatment in MS**

V.I. Leussink, J. Reifenberger, and H.-P. Hartung

[Open Access](#)

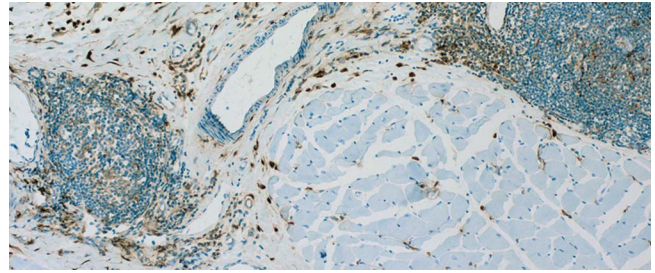
e455 **Pruritus in anti-DPPX encephalitis**

J. Wijntjes, M. Bechakra, M.W.J. Schreurs, J.L.M. Jongen, A. Koppenaal, and M.J. Titulaer

[Open Access](#)

### Correction

e462 **Dramatic rebounds of MS during pregnancy following fingolimod withdrawal**



➔ **Cover image**

Muscle biopsy specimen from an adult patient with follicle-like dermatomyositis, showing CD68+ macrophages distributed at the periphery of ectopic lymphoid structures. See “Architectural B-cell organization in skeletal muscle identifies subtypes of dermatomyositis.”

[See page e451](#)

# Neurology<sup>®</sup> Neuroimmunology & Neuroinflammation

5 (3)

*Neurol Neuroimmunol Neuroinflamm* 2018;5;

**This information is current as of January 1, 2018**

<b>Updated Information &amp; Services</b>	including high resolution figures, can be found at: <a href="http://nn.neurology.org/content/5/3.full.html">http://nn.neurology.org/content/5/3.full.html</a>
<b>Supplementary Material</b>	Supplementary material can be found at: <a href="http://nn.neurology.org/content/suppl/2018/05/07/5.3.DC1">http://nn.neurology.org/content/suppl/2018/05/07/5.3.DC1</a>
<b>Permissions &amp; Licensing</b>	Information about reproducing this article in parts (figures, tables) or in its entirety can be found online at: <a href="http://nn.neurology.org/misc/about.xhtml#permissions">http://nn.neurology.org/misc/about.xhtml#permissions</a>
<b>Reprints</b>	Information about ordering reprints can be found online: <a href="http://nn.neurology.org/misc/addir.xhtml#reprintsus">http://nn.neurology.org/misc/addir.xhtml#reprintsus</a>

*Neurol Neuroimmunol Neuroinflamm* is an official journal of the American Academy of Neurology. Published since April 2014, it is an open-access, online-only, continuous publication journal. Copyright . All rights reserved. Online ISSN: 2332-7812.

