

# An inflammatory milieu

## Optic perineuritis, retroperitoneal fibrosis, and giant cell arteritis

Doria M. Gold, MD and Steven L. Galetta, MD

*Neurol Neuroimmunol Neuroinflamm* 2020;7:e642. doi:10.1212/NXI.0000000000000642

### Correspondence

Dr. Gold  
doria.gold@nyulangone.org

### Case summary

Optic nerve perineuritis targets the optic nerve sheath; it is idiopathic or a manifestation of systemic inflammatory diseases such as myelin oligodendrocyte glycoprotein (MOG) antibody syndrome, sarcoidosis, granulomatosis with polyangiitis, IgG4-related disease, or giant cell arteritis (GCA).<sup>1</sup> Radiographically, there is optic nerve sheath enhancement and, occasionally, orbital fat “streaking.”<sup>1</sup> Biopsies have identified dural sheath lymphocytic infiltrate, perineural fibrous tissue, granulomas, or evidence of small-vessel vasculitis.<sup>1</sup> Retroperitoneal fibrosis (RPF) is defined by abdominal organ fibrosis. Usually idiopathic, it may be secondary to medication, radiation, or systemic inflammatory conditions.<sup>2</sup> Pathologically, its hallmark is fibrosis and infiltration of macrophages, B-lymphocytes, and T-lymphocytes.<sup>2</sup> Often considered when older patients present with headache or ischemic optic neuropathy, GCA is the most common large-vessel vasculitis.<sup>3</sup> It has been proposed that GCA results from a T-cell-mediated inflammatory cascade, causing vascular intimal hyperplasia.<sup>3</sup> GCA has rarely been reported in association with RPF<sup>4,5</sup> or perineuritis.<sup>6,7</sup> We present a patient initially diagnosed with idiopathic RPF treated with immunosuppression, who subsequently developed optic perineuritis followed by GCA.

A 71-year-old man presented to the emergency department with urosepsis and renal insufficiency. He was treated with intravenous (IV) antibiotics for positive urine and blood cultures, but his kidney function remained abnormal. Renal ultrasound revealed bilateral hydronephrosis, and MRI abdomen/pelvis showed a retroperitoneal mass. Biopsy demonstrated patchy fibrosis and soft tissue lymphoplasmacytic infiltrate. IgG antibody staining was negative. He was treated with mycophenolate for 2 years.

Six years later, he presented for having had 5 days of left eye vision loss that remained stable from onset. He endorsed jaw soreness but denied diplopia. Acuity was 20/25 in each eye. He had a trace left afferent pupillary defect, and color plates were performed more slowly on the left. Optic discs were without swelling or pallor. He had normal ocular motility. Humphrey visual fields revealed few nonspecific points of depression in each eye and an inferonasal defect in the left eye that corresponded with his complaint. He had no temporal artery thickening or tenderness. He was sent to the emergency department for blood work and IV steroids for presumed GCA. Erythrocyte sedimentation rate (20 mm/h) and platelets (281,000/mm<sup>3</sup>) were in the normal range, and C-reactive protein was mildly elevated (13 mg/L). IV methylprednisolone was initiated. Chest X-ray was normal. MRI/magnetic resonance angiography of the brain demonstrated mild microvascular ischemic changes and volume loss with normal vasculature. Orbital MRI showed optic nerve sheath enhancement and orbital fat stranding (figure, A and C).

Laboratory workup revealed elevated HgA1c (7.9%), serum glucose (239 mg/dL), and subclinical hypothyroidism (thyroid stimulating hormone 5.980 mIU/L). In addition, there were negative Lyme titers, serum paraneoplastic panel, aquaporin-4 receptor, MOG, and antineutrophil cytoplasmic antibodies. Serum IgG4 levels were not elevated. CSF examination showed red blood cells

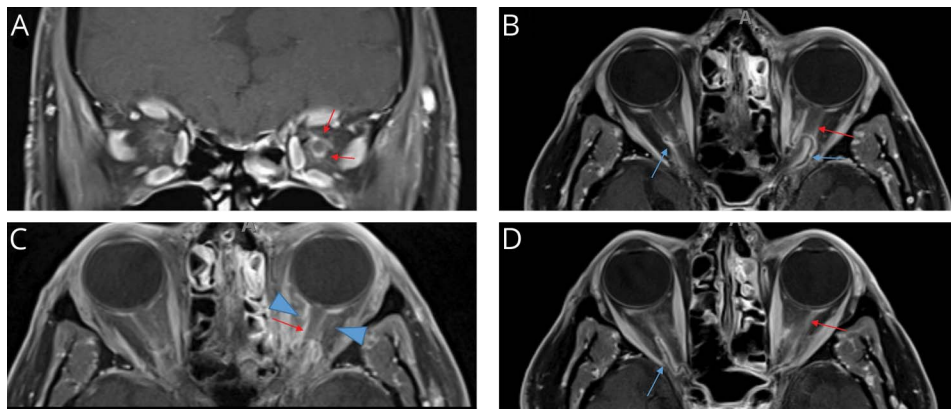
---

From the Department of Neurology (D.M.G.) and Departments of Neurology and Ophthalmology (S.L.G.), NYU Langone Medical Center, New York.

Go to [Neurology.org/NN](https://www.neurology.org/NN) for full disclosures. Funding information is provided at the end of the article.

The Article Processing Charge was funded by the NYU Langone Medical Center Department of Neurology.

This is an open access article distributed under the terms of the Creative Commons Attribution-NonCommercial-NoDerivatives License 4.0 (CC BY-NC-ND), which permits downloading and sharing the work provided it is properly cited. The work cannot be changed in any way or used commercially without permission from the journal.



Coronal (A) and axial (C) MRI orbits at initial presentation demonstrating optic perineuritis (red arrows) and fat stranding (blue arrowheads) left greater than the right. Axial MRI orbits after 6 months demonstrating bilateral thickening and enhancement of the ophthalmic arteries (blue arrows) and improved optic perineuritis (red arrows) (B and D).

3, white blood cells 3, elevated protein (74 mg/dL), elevated glucose (144 mg/dL), negative cytology, flow cytometry, culture, venereal disease research laboratory test (to evaluate for syphilis), and Lyme antibodies. Serum immunoglobulins, CSF IgG index, and oligoclonal bands were not checked.

Corticosteroids were tapered over 5 months. One month after complete discontinuation, he endorsed a new left temporal headache. He denied visual symptoms, jaw claudication, or muscle weakness. Examination was improved with acuity 20/20 OU. Repeat MRI brain/orbits revealed bilateral ophthalmic and superficial temporal artery thickening and enhancement, compatible with GCA. There was near-complete resolution of the left optic perineural enhancement (figure, B and D). Temporal artery biopsy confirmed the diagnosis with lymphocytes, macrophages, granulomatous inflammation, and no IgG4-positive cells. High-dose oral prednisone (1 mg/kg) treatment was initiated and followed by a slow taper, which maintained resolution of headaches. Repeat imaging showed decreased ophthalmic and temporal artery enhancement and resolved optic nerve sheath inflammation. There was no aortic involvement on MRA chest.

Our patient manifested with 3 sequential inflammatory disorders: RPF, optic perineuritis, and GCA. Clinically, each was mild. Although an umbrella of GCA-related vasculitis may be suggested, his course supports a less specific systemic inflammatory process uniquely expressed at 3 different time points. Although the exact pathogenesis of perineuritis, RPF, and GCA typically do not overlap, each condition results from cell-mediated immunologic overactivation, resulting in fibrosis and granulomatous inflammation.

In the few reported cases of perineuritis and GCA, most had bilateral perineural involvement on neuroimaging. In addition, examination often demonstrated optic neuropathy or ocular motility impairment.<sup>6,7</sup> Unlike our patient who rapidly responded to steroids, the optic nerve dysfunction typically did not

improve. In the cases of RPF described with GCA, patients had a more fulminant presentation. Perhaps our patient's immunosuppression for RPF with mycophenolate, which suppresses B-lymphocyte and T-lymphocyte proliferation, dampened the later cell-mediated response. Fortunately, our patient had an indolent course despite tissue and arterial inflammatory changes. To our knowledge, the conditions RPF, perineuritis, and GCA have not been documented in a single patient nor after prolonged immunosuppression.

### Study funding

No targeted funding reported.

### Disclosure

D.M. Gold and S.L. Galetta report no disclosures. Go to [Neurology.org/NN](http://Neurology.org/NN) for full disclosures.

### Publication history

Received by *Neurology: Neuroimmunology & Neuroinflammation* September 23, 2019. Accepted in final form October 23, 2019.

### Appendix Authors

Name	Location	Role	Contribution
<b>Doria M. Gold, MD</b>	NYU Langone Medical Center, New York	Author	Drafting/revising the manuscript, data acquisition, and study concept or design
<b>Steven L. Galetta, MD</b>	NYU Langone Medical Center, New York	Author	Study concept or design, data acquisition, and revised the manuscript for intellectual content

### References

1. Purvin V, Kawasaki A, Jacobson DM. Optic perineuritis: clinical and radiographic features. *Arch Ophthalmol* 2001;119:1299–1306.
2. Vaglio A, Maritati F. Idiopathic retroperitoneal fibrosis. *J Am Soc Nephrol* 2016;27:1880–1889.
3. Watanabe R, Goronzy JJ, Berry G, Liao YJ, Weyand CM. Giant cell arteritis: from pathogenesis to therapeutic management. *Curr Treat Opt Rheumatol* 2016;2:126–137.

4. Protopsaltis I, Sotiropoulos A, Foteinos A, et al. Chronic periaortitis (retroperitoneal fibrosis) concurrent with giant cell arteritis: a case report. *J Med Case Rep* 2014;8:167.
5. Tolle PA, Kesten F, Daikeler T. Giant cell arteritis followed by idiopathic retroperitoneal fibrosis in the same patient—an unexpected positron emission tomography finding. *Rheumatology (Oxford)* 2012;51:1549.
6. Pappolla A, Silveira F, Norscini J, Miquelini L, Patrucco L. Bilateral optic perineuritis as initial presentation of giant cell arteritis. *Neurologist* 2019;24:26–28.
7. Liu TY, Miller NR. Giant cell arteritis presenting as unilateral anterior ischemic optic neuropathy associated with bilateral optic nerve sheath enhancement on magnetic resonance imaging. *J Neuroophthalmol* 2015;35:360–363.

# Neurology<sup>®</sup> Neuroimmunology & Neuroinflammation

**An inflammatory milieu: Optic perineuritis, retroperitoneal fibrosis, and giant cell arteritis**

Doria M. Gold and Steven L. Galetta  
*Neurol Neuroimmunol Neuroinflamm* 2020;7;  
DOI 10.1212/NXI.0000000000000642

**This information is current as of November 26, 2019**

*Neurol Neuroimmunol Neuroinflamm* is an official journal of the American Academy of Neurology. Published since April 2014, it is an open-access, online-only, continuous publication journal. Copyright © 2019 The Author(s). Published by Wolters Kluwer Health, Inc. on behalf of the American Academy of Neurology.. All rights reserved. Online ISSN: 2332-7812.



<b>Updated Information &amp; Services</b>	including high resolution figures, can be found at: <a href="http://nn.neurology.org/content/7/1/e642.full.html">http://nn.neurology.org/content/7/1/e642.full.html</a>
<b>References</b>	This article cites 7 articles, 1 of which you can access for free at: <a href="http://nn.neurology.org/content/7/1/e642.full.html##ref-list-1">http://nn.neurology.org/content/7/1/e642.full.html##ref-list-1</a>
<b>Subspecialty Collections</b>	This article, along with others on similar topics, appears in the following collection(s): <b>Autoimmune diseases</b> <a href="http://nn.neurology.org/cgi/collection/autoimmune_diseases">http://nn.neurology.org/cgi/collection/autoimmune_diseases</a> <b>MRI</b> <a href="http://nn.neurology.org/cgi/collection/mri">http://nn.neurology.org/cgi/collection/mri</a> <b>Secondary headache disorders</b> <a href="http://nn.neurology.org/cgi/collection/secondary_headache_disorders">http://nn.neurology.org/cgi/collection/secondary_headache_disorders</a> <b>Vasculitis</b> <a href="http://nn.neurology.org/cgi/collection/vasculitis">http://nn.neurology.org/cgi/collection/vasculitis</a> <b>Visual loss</b> <a href="http://nn.neurology.org/cgi/collection/visual_loss">http://nn.neurology.org/cgi/collection/visual_loss</a>
<b>Permissions &amp; Licensing</b>	Information about reproducing this article in parts (figures, tables) or in its entirety can be found online at: <a href="http://nn.neurology.org/misc/about.xhtml#permissions">http://nn.neurology.org/misc/about.xhtml#permissions</a>
<b>Reprints</b>	Information about ordering reprints can be found online: <a href="http://nn.neurology.org/misc/addir.xhtml#reprintsus">http://nn.neurology.org/misc/addir.xhtml#reprintsus</a>

*Neurol Neuroimmunol Neuroinflamm* is an official journal of the American Academy of Neurology. Published since April 2014, it is an open-access, online-only, continuous publication journal. Copyright © 2019 The Author(s). Published by Wolters Kluwer Health, Inc. on behalf of the American Academy of Neurology. All rights reserved. Online ISSN: 2332-7812.

