

Myelin Oligodendrocyte Glycoprotein Antibody-Associated Disease Presenting as Intracranial Hypertension

A Case Report

Jaydip Ray Chaudhuri, MD, DM, FEBN, MRCP, Jui Jade Bagul, MD, DM, Alluri Swathi, MBBS, MRCP, Bhim Sen Singhal, MD, DSC, FRCP, FCCP, FAMS, N. Chakradhar Reddy, DM, and Kiran Kumar Vallam, DO, MRCS

Neurol Neuroimmunol Neuroinflamm 2022;9:e200020. doi:10.1212/NXL.0000000000200020

Correspondence

Dr. Chaudhuri
jaydiprc@gmail.com

Abstract

The production of autoantibodies against myelin oligodendrocyte glycoprotein (MOG) can cause a spectrum of autoimmune disorders, including optic neuritis, transverse myelitis, brainstem encephalitis, and acute disseminated encephalomyelitis. In this study, we present the case of a 19-year-old woman with an unusual clinical presentation of intracranial hypertension (IH) and bilateral papilledema. The patient presented with symptoms of increased intracranial pressure, which followed a relapsing, remitting course over several months. Serial CSF studies showed an increased opening pressure during clinical relapses. The CSF and serum tested positive for MOG immunoglobulin G antibodies. Contrast-enhanced MRI of the brain showed mild meningeal enhancement in the left parietal region with subtle underlying cortical hyperintensities, indicating possible fluid-attenuated inversion recovery variable unilateral enhancement of the leptomeninges. The patient responded well to immunosuppressive therapy using rituximab. The presentation of MOG antibody-associated disease (MOGAD) as IH without optic neuritis is rare. This report presents the first description of a relapsing remitting course presenting each time with only symptoms of raised intracranial pressure, without developing any typical clinical manifestations of MOGAD.

From the Yashoda Hospital (J.R.C., A.S., N.C.R., K.K.V.), Hyderabad; and Bombay Hospital Institute of Medical Science (J.J.B., B.S.S.), India.

Go to [Neurology.org/NN](https://www.neurology.org/NN) for full disclosures. Funding information is provided at the end of the article.

The Article Processing Charge was funded by the authors.

This is an open access article distributed under the terms of the Creative Commons Attribution-NonCommercial-NoDerivatives License 4.0 (CC BY-NC-ND), which permits downloading and sharing the work provided it is properly cited. The work cannot be changed in any way or used commercially without permission from the journal.

Myelin oligodendrocyte glycoprotein (MOG) is a glycoprotein found in the myelin sheaths of neurons in the CNS. MOG is an important target for a spectrum of autoimmune disorders, particularly optic neuritis and transverse myelitis. In this study, we report an unusual manifestation of MOG antibody-associated disease (MOGAD) in a young woman who presented with isolated intracranial hypertension (IH).

Case History

A 19-year-old woman developed a severe headache with acute-onset and occasional transient visual obscurations persisting for 1 week. She was evaluated at a local hospital and found to have bilateral papilledema on fundoscopy. The patient had no other neurologic symptoms. MRI of the brain with contrast venogram showed normal results. The results of CSF analysis were normal, but the opening pressure was elevated to 25 cm H₂O (normal range: 6–20 cm H₂O). The patient was subsequently diagnosed with IH. The patient responded to oral acetazolamide at 750 mg daily for 1 month.

After 3 months, the symptoms recurred, with acute-onset severe headache, vomiting, and intermittent blurring of vision, which was greater in the left eye than in the right. The patient was then referred to a tertiary specialist. A detailed history was obtained, and she did not have fever, seizures, or altered sensorium. Fundoscopy revealed persistent bilateral disc edema. Focal neurologic deficits were not observed.

The visual field test results and acuity were normal. Visual evoked potentials (VEPs) were normal. Another brain MRI revealed mild meningeal enhancement in the left parietal region on contrast sequences. Minimal hyperintensity without any diffusion restriction or white matter lesions was further observed in the underlying cortex on fluid-attenuated inversion recovery (FLAIR). Figure 1A shows a postcontrast T1-weighted axial image indicating abnormal unilateral leptomeningeal enhancement along

the left temporoparietal cortical sulci, and Figure 1B shows the minimal hyperintensity of the adjoining cortex on an axial FLAIR image. A repeat CSF tap showed lymphocytic pleocytosis (20 cells) and normal glucose and protein levels. The opening pressure was 35 cm H₂O.

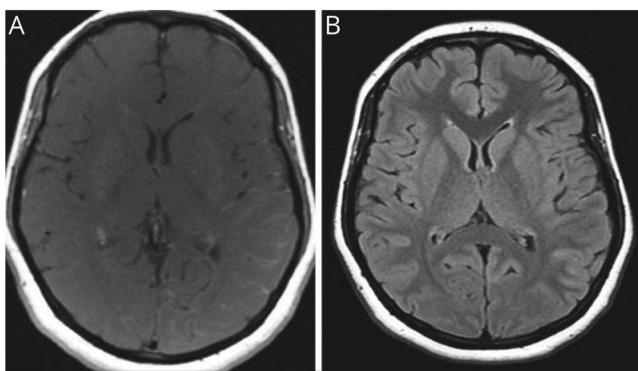
Owing to the presence of minimal cortical FLAIR hyperintensity and leptomeningeal enhancement in the brain MRI associated with CSF pleocytosis, further evaluation was performed. Serum and CSF MOG immunoglobulin (Ig) G antibodies were tested with a cell-based immunoassay using transfected cell lines for qualitative or semiquantitative *in vitro* determination of human IgG antibodies to the aquaporin-4 receptor and anti-MOG positive in serum and CSF (1:10 dilutions).¹ Other workup results for vasculitis and infective and autoimmune encephalitis were negative (including anti-nuclear antibodies, antineutrophil cytoplasmic antibodies, anticardiolipin antibodies, and antibodies to aquaporin-4).

The patient's serum angiotensin-converting enzyme level was normal at 26 nmol/mL/min (normal value, ≤ 40 nmol/mL/min). PET imaging of the entire body, including the brain, revealed normal results. The patient was diagnosed with MOGAD. Her headache subsided, and the papilledema was partially resolved with IV methylprednisolone at 1 g/d for 3 days, followed by oral steroids. However, after initial improvement, her symptoms reappeared while steroids were being tapered.

Mycophenolate mofetil (MMF) was added to the treatment, but despite this, she experienced 4 relapses in 6 months. All relapses presented with headache and signs of increased intracranial pressure (ICP) with papilledema when steroids were tapered, except at the fourth follow-up. Each episode improved after a CSF tap. The serial CSF reports are presented in Table.

In view of the relapses with headache despite treatment with MMF and steroids, IV rituximab was initiated, with positive results. Her symptoms, such as headache and papilledema, subsided, and steroids and MMF were tapered. Papilledema resolved over a period of 2 months. The patient remained asymptomatic even after 1 year (Figure 2).

Figure 1 MRI Brain FLAIR and Contrast



(A) Abnormal leptomeningeal enhancement along the left temporoparietal cortical sulci. (B) Fluid-attenuated inversion recovery (FLAIR) image showing minimal hyperintensity of the adjoining cortex.

Discussion

Antibodies against MOGs (MOG-IgG) cause a wide spectrum of inflammatory demyelinating CNS conditions. Optic neuritis (45.8%), transverse myelitis (22.8%), and brainstem encephalitis (17.1%) are more common presentations in adults, whereas acute disseminated encephalomyelitis is common in children.² A few patients with unusual presentations have been reported to have MOG-IgG positivity, including encephalitis, leukodystrophy, posterior reversible encephalopathy syndrome, multiple sclerosis, meningoencephalitis, and aseptic meningitis.³⁻⁷

In this study, we report a case of a MOG-IgG-positive patient who presented with IH. Although a few such patients with

Table Results of Serial CSF and Laboratory Studies

Date	May 11, 2019	August 2, 2019	October 17, 2019	November 6, 2019	January 13, 2020
CSF cell count	2	20	80	2	3
CSF differential count	100% lymphocyte	100% lymphocyte	90% lymphocyte, 10% polymorph	100% lymphocyte	100% lymphocyte
CSF protein, mg/dL	20	29	83	31	20
CSF glucose, mg/dL	80	61	48	55	54
CSF opening pressure	25 cm of H ₂ O	35 cm of H ₂ O	35 cm of H ₂ O	23 cm of H ₂ O	38 cm of H ₂ O
CSF MOG antibodies	—	Positive	Positive	Negative	Negative
Oligoclonal bands	Negative	Negative	—	—	—
Gene X TB	—	Negative	Negative	—	—
CSF culture	—	Negative	Negative	—	—
Papilledema	Positive	Positive	Positive	Negative	Negative
Serum NMO antibodies	Negative	Negative	—	—	—
Serum MOG antibodies	—	Positive	Strongly positive	Positive	Positive
OCT	Normal retina	—	—	—	—
MRI brain (plain and contrast)	Normal	Mild leptomeningeal enhancement	—	Normal	—

Abbreviations: MOG = myelin oligodendrocyte glycoprotein; NMO = neuromyelitis optica; OCT = optical coherence tomography; TB = tuberculosis.

IH have been reported, they ultimately developed other presentations of MOGAD, which aided in the diagnosis.⁴⁻⁶ The patient had several relapses of IH but did not develop any of the typical clinical features, which is unusual for MOGAD. Our patient had elevated ICP and bilateral papilledema. Although bilateral optic neuritis affecting the anterior optic nerve may be confused with papilledema,⁸ visual complaints and investigations, including VEP, were not consistent with optic neuritis and favored papilledema because of raised ICP. The CSF opening pressure was elevated in multiple taps, and clinical symptoms resolved after CSF drainage. A few cases have been reported with increased CSF pressure in MOGAD, but this is usually accompanied by acute disseminated encephalomyelitis or meningoencephalitis.⁵⁻⁷

Lymphocytic pleocytosis was identified in a few subsequent CSF studies, which is consistent with the findings of other studies (50%–66%).⁹ To the best of our knowledge, raised ICP without other features as a presentation of MOGAD has not been reported. A possible mechanism in our patient could involve low-grade meningeal inflammation producing excessive CSF.

Neuroimaging revealed meningeal enhancement with minimal hyperintensity in the underlying cortex. Most MRI studies on patients with MOGAD have shown meningeal bystander inflammation overlying a cord lesion or accompanying brain lesions.¹⁰ The MRI results of this patient likely

indicate FLAIR-variable unilateral enhancement of the leptomeninges, which is a rare, newly recognized finding in MOGAD.¹¹

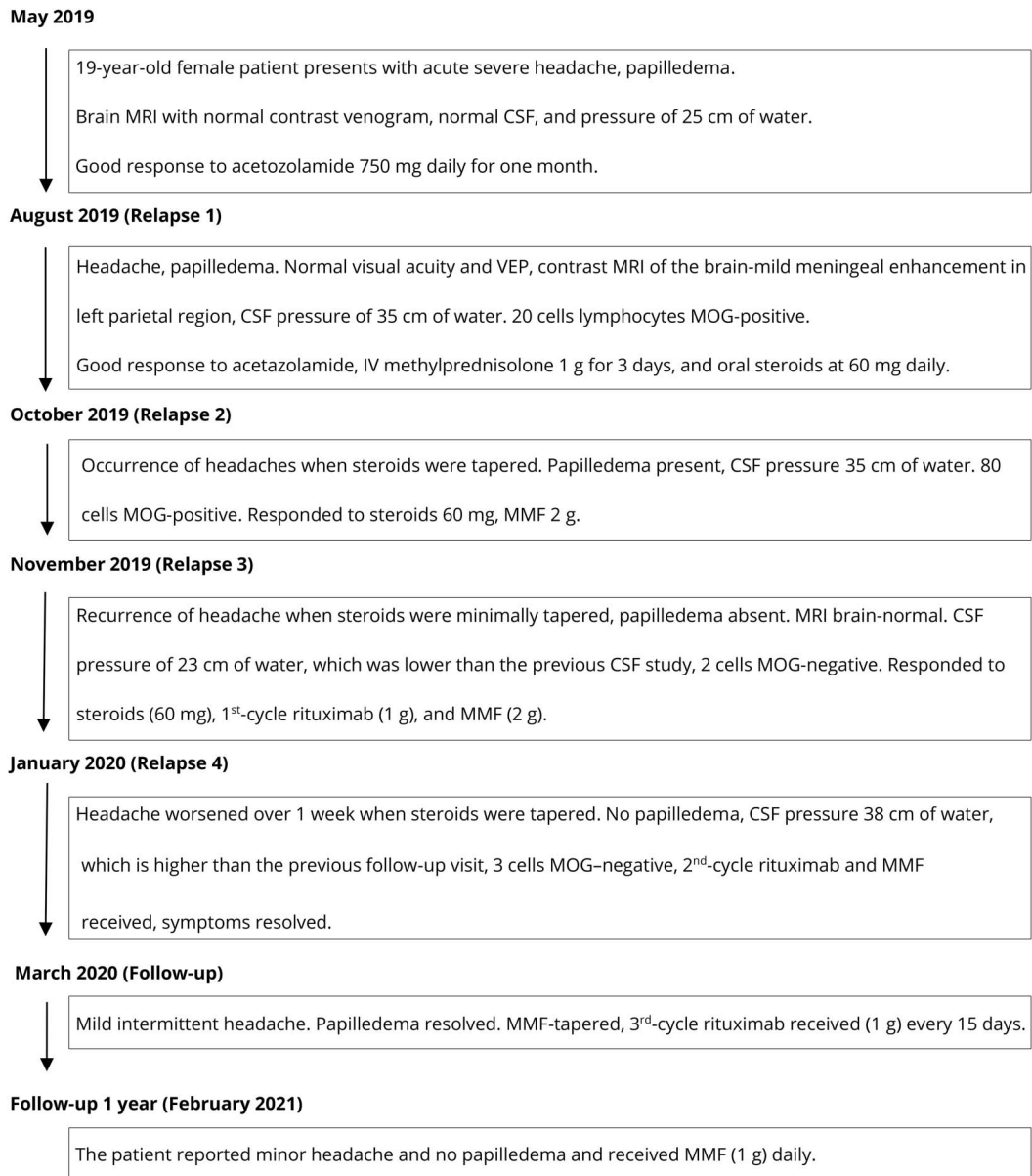
A small study performed on 34 diagnosed patients with IH to determine the presence of MOG-IgG antibodies did not identify a single patient who was positive for the antibody.¹² Conversely, our patient consistently had positive results for MOG-IgG antibody in CSF and serum, even with subsequent relapses. Strongly positive test results and the presence of neutrophils in CSF coincided with the onset of a new relapse. The patient also had an ill-sustained response to steroids and MMF, as has been noted in the literature.¹³ Her response to rituximab was good, as evidenced by clinical improvement, resolved papilledema, and negative CSF MOG results.

In conclusion, our results widen the spectrum of MOGAD. Along with common presentations such as optic neuritis and transverse myelitis, our case broadens the clinical spectrum to include unusual presentations such as idiopathic IH, especially in cases of relapse, and without a response to usual therapy. A high degree of suspicion of MOGAD as a cause of isolated IH can help provide specific treatment and improve outcomes.

Acknowledgment

The authors thank Dr. Lingaiah A, Director of Medical Services, and director Dr. Pavan for their immense support and also acknowledge the contributions of Dr. Sunila Jaggi,

Figure 2 Flowchart of the Clinical Course of Patient Treatment



MMF = mycophenolate mofetil; MOG = myelin oligodendrocyte glycoprotein.

Bombay Hospital Institute of Medical Sciences, for detailed analysis of MRI images.

Study Funding

No targeted funding reported.

Disclosure

The authors report no disclosures relevant to the manuscript. Go to Neurology.org/NN for full disclosures.

Publication History

Received by *Neurology: Neuroimmunology & Neuroinflammation* December 5, 2021. Accepted in final form June 27, 2022. Submitted and externally peer reviewed. The handling editor was Josep O. Dalmau, MD, PhD, FAAN.

Appendix Authors

Name	Location	Contribution
Jaydip Ray Chaudhuri, MD, DM, FEBN, MRCP	Yashoda Hospital, Hyderabad, India	Drafting/revision of the manuscript for content, including medical writing for content; major role in the acquisition of data; study concept or design; analysis or interpretation of data
Jui Jade Bagul, MD, DM	Bombay Hospital Institute of Medical Science, India	Drafting/revision of the manuscript for content, including medical writing for content; major role in the acquisition of data; study concept or design; analysis or interpretation of data

Appendix (continued)

Name	Location	Contribution
Alluri Swathi, MBBS, MRCP	Yashoda Hospital, Hyderabad, India	Drafting/revision of the manuscript for content, including medical writing for content; major role in the acquisition of data; study concept or design; analysis or interpretation of data
Bhim Sen Singhal, MD, DSC, FRCP, FCCP, FAMS	Bombay Hospital Institute of Medical Science, India	Drafting/revision of the manuscript for content, including medical writing for content; major role in the acquisition of data; study concept or design; analysis or interpretation of data
N. Chakradhar Reddy, DM	Yashoda Hospital, Hyderabad, India	Drafting/revision of the manuscript for content, including medical writing for content; major role in the acquisition of data; study concept or design; analysis or interpretation of data
Kiran Kumar Vallam, DO, MRCS	Bombay Hospital Institute of Medical Science, India	Drafting/revision of the manuscript for content, including medical writing for content; major role in the acquisition of data; study concept or design; analysis or interpretation of data

References

1. Waters PJ, Komorowski L, Woodhall M, et al. A multicenter comparison of MOG-IgG cell-based assays. *Neurology*. 2019;92(11):e1250-e1255.
2. Netravati M, Holla VV, Nalini A, et al. Myelin oligodendrocyte glycoprotein-antibody-associated disorder: a new inflammatory CNS demyelinating disorder. *J Neurol*. 2021;268(4):1419-1433.
3. Hacoohen Y, Rossor T, Mankad K, et al. 'Leukodystrophy-like' phenotype in children with myelin oligodendrocyte glycoprotein antibody-associated disease. *Dev Med Child Neurol*. 2018;60(4):417-423.
4. Corbett J, Bhuta S, Prain K, Brilot F, Sabet A, Broadley SA. PRES-like presentation in MOG antibody-related demyelination (MARD). *J Clin Neurosci*. 2020;72:453-455.
5. Narayan RN, Wang C, Sguigna P, Husari K, Greenberg B. Atypical Anti-MOG syndrome with aseptic meningoencephalitis and pseudotumor cerebri-like presentations. *Mult Scler Relat Disord*. 2019;27:30-33.
6. Lotan I, Brody J, Hellmann MA, et al. Myelin oligodendrocyte glycoprotein-positive optic neuritis masquerading as pseudotumor cerebri at presentation. *J Neurol*. 2018; 265(9):1985-1988.
7. Nagabushana D, Shah R, Pendharkar H, et al. MOG antibody seropositive aseptic meningitis: a new clinical phenotype. *J Neuroimmunol*. 2019;333:476960.
8. Chen JJ, Flanagan EP, Jitraprakulsan J, et al. Myelin oligodendrocyte glycoprotein antibody-positive optic neuritis: clinical characteristics, radiologic clues, and outcome. *Am J Ophthalmol*. 2018;195:8-15.
9. Jarius S, Pellkofer H, Siebert N, et al. Cerebrospinal fluid findings in patients with myelin oligodendrocyte glycoprotein (MOG) antibodies. Part 1: results from 163 lumbar punctures in 100 adult patients. *J Neuroinflammation*. 2020; 17(1):261.
10. Deneve M, Biotti D, Patsoura S, et al. MRI features of demyelinating disease associated with anti-MOG antibodies in adults. *J Neuroradiol*. 2019;46(5):312-318.
11. Adrian B, Amy K, Eoin F. Adding FUEL to FLAMES: FLAIR-variable unilateral enhancement of the leptomeninges (FUEL) in MOG-IgG-associated disease. *Neurology*. 2020;94(15 suppl):862.
12. Altiokka-Uzun G, Erdag E, Baykan B, et al. Glial and neuronal antibodies in patients with idiopathic intracranial hypertension. *Neurol Sci*. 2017;38(10):1817-1822.
13. Ramanathan S, Mohammad S, Tantsis E, et al. Clinical course, therapeutic responses and outcomes in relapsing MOG antibody-associated demyelination. *J Neurol Neurosurg Psychiatry*. 2018;89(2):127-137.

Neurology[®] Neuroimmunology & Neuroinflammation

Myelin Oligodendrocyte Glycoprotein Antibody-Associated Disease Presenting as Intracranial Hypertension: A Case Report

Jaydip Ray Chaudhuri, Jui Jade Bagul, Alluri Swathi, et al.
Neurol Neuroimmunol Neuroinflamm 2022;9;
DOI 10.1212/NXI.0000000000200020

This information is current as of October 19, 2022

Updated Information & Services	including high resolution figures, can be found at: http://nn.neurology.org/content/9/6/e200020.full.html
References	This article cites 13 articles, 1 of which you can access for free at: http://nn.neurology.org/content/9/6/e200020.full.html##ref-list-1
Subspecialty Collections	This article, along with others on similar topics, appears in the following collection(s): Acute disseminated encephalomyelitis http://nn.neurology.org/cgi/collection/acute_disseminated_encephalomyelitis All Demyelinating disease (CNS) http://nn.neurology.org/cgi/collection/all_demyelinating_disease_cns MRI http://nn.neurology.org/cgi/collection/mri Optic neuritis; see Neuro-ophthalmology/Optic Nerve http://nn.neurology.org/cgi/collection/optic_neuritis
Permissions & Licensing	Information about reproducing this article in parts (figures, tables) or in its entirety can be found online at: http://nn.neurology.org/misc/about.xhtml#permissions
Reprints	Information about ordering reprints can be found online: http://nn.neurology.org/misc/addir.xhtml#reprintsus

Neurol Neuroimmunol Neuroinflamm is an official journal of the American Academy of Neurology. Published since April 2014, it is an open-access, online-only, continuous publication journal. Copyright Copyright © 2022 The Author(s). Published by Wolters Kluwer Health, Inc. on behalf of the American Academy of Neurology.. All rights reserved. Online ISSN: 2332-7812.

